

The Diagnosis and Treatment of Robert's Uterus: A Case Report and Literature Review

Liu H^{1,2,3}, Wang Q², Zhang H¹ and Dang Q^{1,2,3,*}

¹Department of Gynecology, Henan Provincial People's Hospital, Zhengzhou, China

²Henan University People's Hospital, Zhengzhou, China

³Zhengzhou University People's Hospital, Zhengzhou, China

Volume 4 Issue 7- 2020

Received Date: 24 July 2020

Accepted Date: 04 Aug 2020

Published Date: 08 Aug 2020

2. Key words

Robert's uterus; Dysmenorrhoea; Surgery; Treatment; Management

1. Abstract

1.1. Background: Robert's uterus is a very rare malformation and are associated with a severe dysmenorrhoea. It is rarely reported.

1.2. Case history: A 15-year-old girl was referred to our hospital for dysmenorrhoea. She was suspected of Robert's uterus due MRI and ultrasound, which showed an asymmetric septate uterus with one blind cavity, causing menstrual retention and severe dysmenorrhoea. She underwent hysteroscopy and laparoscopy and Robert's uterus was confirmed. The surgery was performed with satisfactory results. The patient returned for a follow-up examination in the third month after surgery. By then, she had had three menstrual periods, and her dysmenorrhoea was cured. Follow-up is still needed to pay attention to her pregnancy and fertility.

1.3. Conclusion: The early diagnosis of Robert's uterus is still difficult. Paediatricians, gynaecologists and surgeons should be alert to the possibility of uterine malformations when assessing dysmenorrhoea in adolescents. Timely diagnosis and minimally invasive surgery are important for the patient's future pregnancy.

3. Introduction

Robert's uterus is a rare malformation described as an asymmetric septate uterus with a non-communicating cavity. As a result, there is obstruction to the menstrual flow in the blind cavity, resulting in different degrees of primary dysmenorrhoea and even affecting fertility in adulthood. This rare uterine malformation was first reported and named "Robert's uterus" by Robert in 1970. Recently, a patient with Robert's uterus was admitted to our hospital. Her clinical data are reported herein. In addition, the relevant literature is reviewed to enhance the recognition of Robert's uterus.

4. Case Report

A 15-year-old girl was admitted to the hospital for "dysmenorrhoea for 2 years" on 17 October 2019. The patient established menarche at the age of 13 and had had regular menstrual cycles every 25 days with a duration of 3-7 days. The pain started and became more serious only a few months after her menarche. The patient presented to another hospital two months later with these complaints and was diagnosed with appendicitis. She underwent an open appendectomy. However, her symptoms persisted in the postoperative period. Her last menstrual period was 6 October 2019. On ultrasonographic examination, a uterine anomaly was suspected, and

the imaging showed a left unilateral uterus and right residual horn uterus with haematometra (endometrial type). Urinary tract ultrasound indicated that both kidneys, the bladder, and the ureters were normal. On physical examination, the patient was generally in good condition, and a scar from previous surgery was noted (a right lower abdomen scar). Gynaecological examination showed female vulva and a single vaginal introitus. Recto-abdominal examination indicated the following: uterine position, flat; uterine size, normal; mobility was normal with no tenderness when pressure was applied; and both adnexa had no obvious abnormality. She was further evaluated with MRI, which revealed a unicornuate uterus and a right ovarian chocolate cyst (Figure 1, 2). During hysteroscopy, a single vagina, single cervix, left uterine cavity and left fallopian tube opening could be seen (Figure 3, 4). We performed laparoscopy on 22 October 2019. During the laparoscopic surgery, the basilar part of the uterus was wide but continuous; the right uterine corner bulged outward, and the left corner was normal; the bilateral fallopian tubes, ovaries, and round ligaments were attached at the normal position, and the right fallopian tube was not thickened. Red-brown endometriosis lesions could be seen on the peritoneum outside the bilateral uterine sacral ligaments (Figure 5). Robert's uterus was suspected. Hysteroscopy under laparoscop-

*Corresponding Author (s): Qun Dang, Department of Gynecology, Henan University People's Hospital, Zhengzhou, Henan, 450003, China, E-mail: dangjunyang@126.com

Citation: Dang Q. The Diagnosis and Treatment of Robert's Uterus: A Case Report and Literature Review Annals of Clinical and Medical Case Reports. 2020; 4(7): 1-5.

ic monitoring for septum resection was performed immediately. First, the septum was cut close to the uterine fundus and to the right, the septum tissue was thicker. A visible brown viscous liquid flowing out of the right uterine cavity was observed when it was opened. Finally, the uterine cavity appeared approximately normal when we removed all of the septum tissue (Figure 6). The uterine cavity was cleaned repeatedly by irrigation (physiological saline). At the same time, the right uterine horn was no longer bulging. An intrauterine balloon stent and anti-adhesion membrane were placed in the uterine cavity to prevent adhesion. There was no application of oestrogen. By two months after the operation, the patient had had 3 menstrual periods without dysmenorrhoea. The results of the re-examination of hysteroscopy showed that the shape of the uterine cavity was almost normal and without adhesion; the endometrial glands at the right uterine horn and the opening of the right fallopian tube were visible (Figure 7, 8, 9).

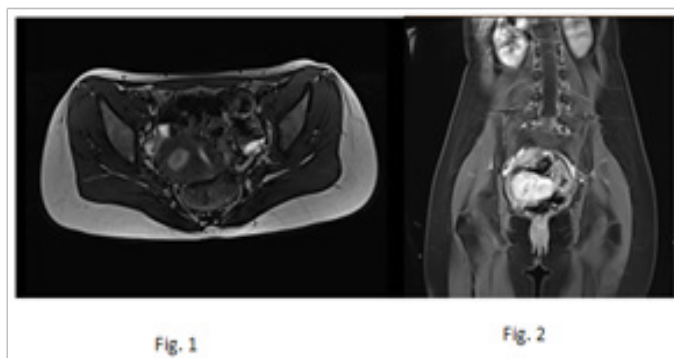


Figure 1, 2: Preoperative MRI.

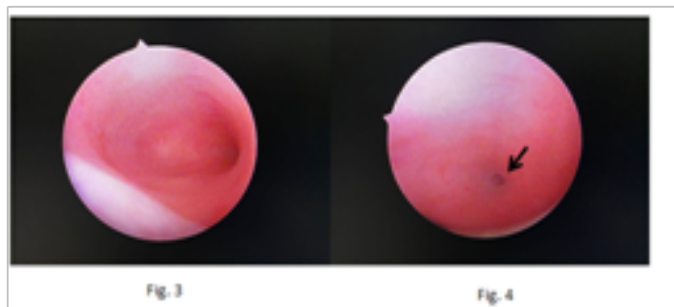

Figure 3: Preoperative intrauterine morphology. Figure 4: Left fallopian tube opening.

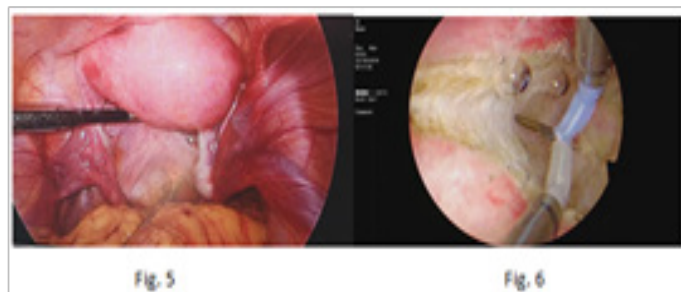


Figure 5: During the laparoscopy. Figure 6: Cutting of the septum.

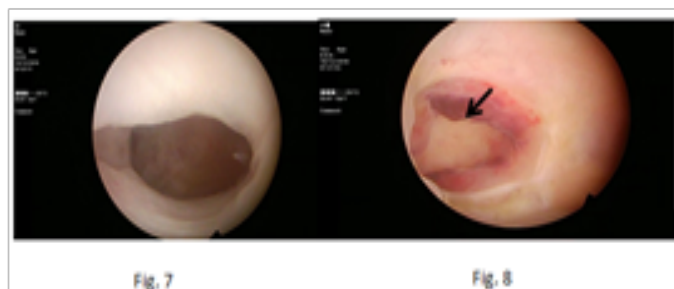

Figure 7: Normal postoperative intrauterine morphology. Figure 8: Right uterine horn.

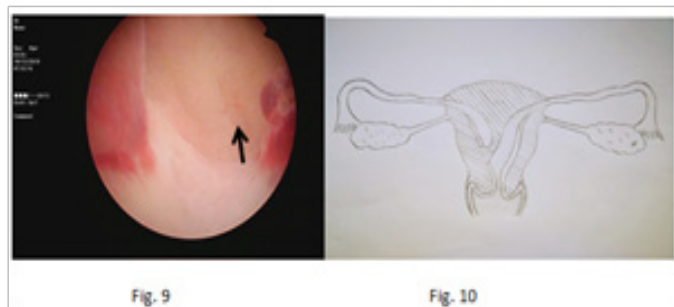


Figure 9: Right fallopian tube opening. Figure 10: A sketch of Robert's uterus.

5. Discussion

5.1. Origin of Robert's uterus

The prevalence of congenital uterine malformation is approximately 5.5-6.7% in the general population [1, 2]. Robert's uterus is an uncommon uterine malformation. Some scholars have classified it as an asymmetric complete septate uterus, in which the mediastinum is biased to one side of the uterine cavity, making it a blind cavity that is not connected to the contralateral vagina, cervix and uterine cavity. It has also been called an "oblique septum uterus" (Figure 10) [3]. It was first reported and named "Robert's uterus" by Robert in 1970 [4] and has been classified as a complete septum uterine subtype (U2b) in the classification method of female genital dysplasia jointly developed by the European Society for Human Reproduction and Embryology (ESHRE) and the European Gynaecological Endoscopy Society (ESGE) [5]. In 2015, there was consensus among Chinese experts on the unified naming and definition of female genital malformations. The Chinese Medical Association's Obstetrics and Gynaecology Branch recommended the abolition of "oblique septum uterus" and "blind uterine horn", which were unified internationally under the name "Robert's uterus" [6]. We searched the literature and found that studies of Robert's uterus were all case reports. To date, there have been fewer than 50 cases at home and abroad.

5.2. Diagnosis of Robert's uterus

The mediastinum of Robert's uterus is on one side of the uterine cavity, and the uterine cavity is completely closed. Menstrual cramps occur when menstrual blood in the blind cavity cannot be

discharged, resulting in blood accumulation and increased intraluminal pressure, in turn causing abdominal pain that gradually worsens [7]. If there is menstrual blood reflux into the peritoneal cavity along the fallopian tube, it may cause the occurrence of endometriosis [8]. Therefore, the typical clinical manifestations of Robert's uterus are periodic abdominal pain and dysmenorrhoea [4, 5, 7]. Some scholars have characterized Robert's uterus as including (i) primary dysmenorrhoea; (ii) discordance due to a normal laparoscopic appearance and hystero-graphic appearance of a unicornuate uterus; and (iii) the absence of anomalies of the urinary system [8]. This patient met the basic characteristics above. In contrast, Vural M et al. [10] found a Robert's uterus without an obvious history of dysmenorrhoea.

Ultrasound has an important role in the diagnosis of uterine malformations. Currently, 3-dimensional ultrasound is widely used in clinical practice, which can make up for deficiencies of the 2-dimensional ultrasound coronal plane and can display the internal structure and external shape of the uterine cavity as a whole. However, there are still limitations in the type of septate uterus [14], which usually indicates a unicornuate uterus with a rudimentary uterine horn (with endometrial type), which is haematometra in the rudimentary uterine horn. Hysterosalpingography (HSG) findings often cause Robert's uterus to be mistaken as a unicornuate uterus with or without a rudimentary uterus [10]. Maddukuri, SB et al. [11] deemed MRI to be an effective and noninvasive method to diagnose Robert's uterus. MRI shows a septate uterus with a normal outer contour. The one-sided cavity is obstructed with associated haematometra, and the ipsilateral fallopian tube is thickened or normal. Hysteroscopy only demonstrates one uterine horn and the ipsilateral fallopian tube opening. Laparoscopy illustrates that the uterine fundus is normal or that the uterine horn bulges on one side, and the ipsilateral fallopian tube is thickened or normal. Hysteroscopy combined with laparoscopy or ultrasound can improve diagnostic accuracy. Therefore, some scholars consider laparoscopy and/or ultrasound combined with hysteroscopy as the "gold standard" for the diagnosis of Robert's uterus [12]. This patient was finally diagnosed during hysteroscopy and laparoscopy. Other scholars have noted that the skills and experience of laparoscopic gynaecologists are another important factor in identifying and managing abnormal uterine deformities [13].

At present, the studies of Robert's uterus are all case reports, most of which are diagnosed during surgery. Consequently, Robert's uterus still lacks effective early diagnosis.

5.3. Differential diagnosis of Robert's uterus

Robert's uterus is relatively rare and easily misdiagnosed or missed. It mainly needs to be distinguished from the following diseases: 1 appendicitis, 2 rudimentary uterine horn, 3 oblique vaginal septum.

3.1 Two cases have been reported in the literature to be misdiagnosed as appendicitis, and the appendix was removed in each instance. However, the symptoms persisted in the postoperative period [15, 16].

3.2 The clinical symptoms of Robert's uterus are similar to those of a functional rudimentary uterine horn, which is difficult to distinguish from a type II rudimentary uterine horn. The incidence of a rudimentary uterus is 1/40,000-1/10,000, that of a functional rudimentary uterine horn is 1/400,000 [17], and that of a unicornuate uterus is approximately 1/4,020-1/1,000 [18]. These incidences are much higher than that of Robert's uterus, which may cause doctors to misdiagnose it. The identification of Robert's uterus and uterus unicornis combined with a rudimentary uterine horn is based on the fact that the rudimentary uterine horn is separated from the uterine base of the unicornuate uterus. The rudimentary uterine horn has a normal fallopian tube and ovary, often accompanied by abnormal urinary organ development on the ipsilateral side [19]. The bottom of Robert's uterus is continuous. Therefore, combined hysteroscopy with laparoscopy is considered to have important value in the differential diagnosis. This case was misdiagnosed as a rudimentary uterine horn before surgery and was confirmed as Robert's uterus during surgery.

3.3 The vaginal oblique diaphragm is often accompanied by the lack of an ipsilateral kidney or ureter. It can be distinguished by gynaecological examination, ultrasound and/or MRI [20].

5.4. Treatment of Robert's uterus

Surgery is the only effective treatment for Robert's uterus; therapeutic options include open surgery and minimally invasive surgery.

Capito C et al. reported a case of Robert's uterus. They opened the abdomen to remove the endometrium of the closed cavity and reconstructed the uterine wall [22]. When the anomaly is combined with pelvic adhesions or endometriosis, laparotomy is an effective way to resect the septum of Robert's uterus [11, 15, 21]. The laparotomy is sutured as much as possible to restore the normal anatomical structure properly. However, it causes certain damage to the uterine wall and even affects further pregnancy.

Minimally invasive surgery includes hysteroscopy, hysteroscopy under the surveillance of a laparoscope and/or ultrasound. Hysteroscopy alone can remove the septum of Robert's uterus [2]. However, this procedure poses a risk of uterine perforation. Kiyak H et al. reported a case of a patient with Robert's uterus who refused vaginal surgery due to virginity and religious beliefs. Finally, she underwent a simple laparoscopic resection of the blind endometrial cavity [23]. Hysteroscopy with laparoscope monitoring can determine the internal and external characteristics of the uterus, making a clear diagnosis and avoiding missing endometriosis. If there are other lesions in the pelvis, coagulation of the lesions

and monitoring of the uterus can be performed to avoid damage. Hysteroscopy combined with ultrasound monitoring can clarify the width and thickness of the septum, prompting the position and direction of cutting the septum and reducing surgical trauma. Combined laparoscopy and/or ultrasound monitoring has the advantages of both techniques. During the operation, the septum is generally cut from the uterine fundus and should be removed as soon as possible to restore the normal uterine cavity shape, which is of great significance for future pregnancy.

Compared with open surgery, hysteroscopy with laparoscopic and/or ultrasound monitoring has the advantages of less trauma and faster recovery. This patient underwent hysteroscopy combined with laparoscopy, which is minimally invasive and safe.

It has been reported that intrauterine pregnancy is still possible on the uterine atresia side, and laparotomy and hysteroscopy may treat this condition. Singhal S et al. reported an intrauterine pregnancy on the side of Robert's uterine atresia. They opened the incision of the uterine septum, removed the stillbirth, and ligated the ipsilateral fallopian tube [8]. Mr Yang et al. reported a pregnancy in a blind hemi-cavity of Robert's uterus with an ipsilateral renal anomaly. The patient was treated by hysteroscopy with laparoscopic and ultrasound guidance. The pregnancy was removed, and the asymmetric septum was resected [25].

5. 5. Postoperative Management and Pregnancy

After surgical removal of the septum of Robert's uterus, intrauterine adhesion needs to be prevented. Methods include oestrogen and progesterone cycle therapy, or placing a hyaluronic acid gel, Foley balloon, or intrauterine device (IUD) into the uterus [12]. Menstrual and dysmenorrhoea symptoms must be regularly observed after surgery and follow-up. Gynaecological ultrasound or hysteroscopy can be performed during the follow-up [26, 27]. An anti-adhesion membrane and a Foley balloon were placed in this patient's uterine cavity. Two months after surgery, the patient in this article had no dysmenorrhoea during her menstrual cycle. Hysteroscopy indicated that the morphology of the uterine cavity was normal without adhesions. Since the patient is under the age of marriage and childbearing, follow-up is still needed to pay attention to her pregnancy and fertility.

Three cases of pregnancy and successful childbirth following Robert's hysteroplasty have been reported, and all new borns survived [9, 21, 24]. Early diagnosis and timely surgery have important implications for quality of life and future pregnancy. Early diagnosis of Robert's uterus is still a challenge. To avoid misdiagnosis and missed diagnosis, paediatricians, gynaecologists and surgeons should be alert to the possibility of uterine malformations when assessing dysmenorrhoea in adolescents. The possibility of Robert's uterus should be considered when diagnosing and treating endometriosis and infertility caused by uterine malformations. Hyster-

oscopy with the assistance of a laparoscope with or without ultrasound is an effective minimally invasive treatment programme.

Authors Contributions: Liu H and Wang Q, These authors contributed equally to this work. All authors have made substantial intellectual contributions to the article and given approval of the final manuscript to be published. HLL was involved in the conception of the article, data collection and management, manuscript writing. WQQ was involved in images collection, data analysis and manuscript writing. HZ was involved in the acquisition of the data and reviewing the literature. QD was involved in the design of the article, manuscript review and editing.

References:

1. Saravelos SH, Cocksedge KA, Li TC. Prevalence and diagnosis of congenital uterine anomalies in women with reproductive failure: a critical appraisal[J]. *Hum Reprod Update*. 2008; 14(5): 415-429.
2. Chan Y Y, Jayaprakasan K, Zamorra J, et al. The prevalence of congenital uterine anomalies in unselected and high-risk populations: a systematic review[J]. *Hum Reprod Update*. 2011; 17(6): 761-771.
3. Spitzer RF, Caccia N, Kives S, et al. Hysteroscopic unification of a complete obstructing uterine septum: case report and review of the literature[J]. *Fertil Steril*. 2008; 90(5): 2016.e17-e20.
4. Robert H. Asymmetrical bifidities with unilateral menstrual retention (apropos of 12 cases) [J]. *Chirurgie*, 1970; 96(11): 796-799.
5. Grimbizis G, Gordts S, Di Spiezio Sardo A, et al. The ESHRE/ESGE consensus on the classification of female genital tract congenital anomalies [J]. *Hum Reprod*, 2013; 28(8): 2032-2044.
6. Chinese association of obstetrics and gynecology. Chinese expert consensus on the unified naming and definition of female genital malformations. [J] *Chin J Obstet Gynecol*. 2015; (9): 648-651 (in Chinese).
7. Benzineb N, Bellasfar M, Merchaoui J, et al. Robert's uterus with menstrual retention in the blind cavity[J]. *J Gynecol Obstet Biol Reprod (Paris)*. 1993; 22(4): 366-368.
8. Singhal S, Agarwal U, Sharma D, et al. Pregnancy in asymmetric blind hemicavity of Robert's uterus: a previously unreported phenomenon[J]. *Eur J Obstet Gynecol Reprod Biol*, 2003; 107(1): 93-95.
9. Vural M, Yildiz S, Cece H, et al. Favourable pregnancy outcome after endometrectomy for a Robert's uterus[J]. *J Obstet Gynaecol*. 2011; 31(7): 668-669.
10. Braun P, Grau FV, Pons RM, et al. Is hysterosalpingography able to diagnose all uterine malformations correctly? A retrospective study[J]. *Eur J Radiol*. 2005; 53(2): 274-279.
11. Maddukuri SB, Karegowda LH, Prakashini K, et al. Robert's uterus: a rare congenital müllerian duct anomaly causing haematometra[J]. *BMJ Case Rep*. 2014; 2014: bcr2014204489.
12. Xia E, Eleven Cases Robert's Uterus Treated by Hysteroscopy and Laparoscopy Successfully Delivered in 1 Case[J]. *J Minim Invasive Gynecol*. 2015; 22(6S): S192-S193.
13. Biler A, Akdemir A, Peker N, et al. A Rare Uterine Malformation:

- Asymmetric Septate Uterus[J]. *J Minim Invasive Gynecol.* 2018; 25(1): 28-29.
14. Deutch TD, Abuhamad AZ, The role of 3-dimensional ultrasonography and magnetic resonance imaging in the diagnosis of müllerian duct anomalies: a review of the literature. [J]. *J Ultrasound Med.* 2008; 27(3): 413-23.
 15. Shi HR, Ren F, Chen ZM, Guo RX. Robert's uterus: Two cases. [J] *Chin J Obstet Gynecol* 2009; 44: 799 (in Chinese).
 16. John SK, Prabhu PS, Virman S, et al. Misdiagnosed Roberts Uterus Leading to Surgical Misadventures[J]. *J Pediatr Adolesc Gynecol.* 2017; 30(4): 508-510
 17. Chopra S, Keepanasseril A, Rohilla M, et al. Obstetric morbidity and the diagnostic dilemma in pregnancy in rudimentary horn: retrospective analysis. [J]. *Arch Gynecol Obstet.* 2009; 280(6): 907-10.
 18. Liatsikos SA, Tsikouras P, Souftas V, et al. Diagnosis and laparoscopic management of a rudimentary uterine horn in a teenage girl, presenting with haematometra and severe endometriosis: our experience and review of literature [J]. *Minim Invasive Ther Allied Technol.* 2010; 19(4): 241-247.
 19. Schneiderman M, Tulandi T. The Importance to Exclude the Existence of a Rudimentary Uterine Horn in Women with Unicornuate Uterus.[J]. *J Obstet Gynaecol Can.* 2018; 40(2): 143-144.
 20. Gai YH, Fan HL, Yan Y, et al. Ultrasonic evaluation of congenital vaginal oblique septum syndrome: A study of 21 cases[J]. *Exp Thered.* 2018; 16(3): 2066-2070.
 21. Gupta N, Mittal S, Dadhwal V, et al. A unique congenital müllerian anomaly: Robert's uterus[J]. *Arch Gynecol Obstet.* 2007; 276(6): 641-643.
 22. Capito C, Sarnacki S, Menstrual retention in a Robert's uterus[J]. *J Pediatr Adolesc Gynecol.* 2009; 22(5): e104-e106.
 23. Kiyak H, Karacan T, Wetherilt LS, et al. Laparoscopic Blinded Endometrial Cavity Resection for Robert's Uterus.[J]. *J Minim Invasive Gynecol.* 2018; 25(2): 340.
 24. Li J, Yu W, Wang M, et al. Hysteroscopic treatment of Robert's uterus with laparoscopy[J]. *J Obstet Gynaecol Res.* 2015; 41(9): 1491-1494.
 25. Yang QM, Li H, He SH, et al. Pregnancy in a blind hemi-cavity of Robert's uterus with ipsilateral renal agenesis: a case report and literature review [J]. *J Int Med Res.* 2019; 47(7): 3427-3434.
 26. Di Spiezio Sardo A, Giampaolino P, Scognamiglio M, et al. An Exceptional Case of Complete Septate Uterus With Unilateral Cervical Aplasia (Class U2bC3V0/ESHRE/ESGE Classification) and Isolated Müllerian Remnants: Combined Hysteroscopic and Laparoscopic Treatment[J]. *J Minim Invasive Gynecol.* 2016; 23(1): 16-17.
 27. Ludwin A, Ludwin I, Bhagavath B, et al. Pre-, intra-, and postoperative management of Robert's uterus[J]. *Fertil Steril.* 2018; 110(4): 778-779.