

Uncommon Cause of Gastrointestinal Bleeding

Vickovic S^{1,2*} and Zec R³

¹Department of Anesthesia, Clinical Centre of Vojvodina, Novi Sad, Serbia

²Faculty of Medicine, University of Novi Sad, Novi Sad, Serbia

³Department of Gastroenterology and Hepatology, General Hospital Sremska Mitrovica, Serbia

*Corresponding author:

Sanja Vickovic, Department of Anesthesia,
Clinical Centre of Vojvodina, Novi Sad,
Faculty of Medicine, University of Novi Sad,
Novi Sad, Serbia,
E-mail: sanja.vickovic@mf.uns.ac.rs

Received: 21 Jan 2021

Accepted: 18 Feb 2021

Published: 22 Feb 2021

Copyright:

©2021 Vickovic S et al., This is an open access article distributed under the terms of the Creative Commons Attribution License, which permits unrestricted use, distribution, and build upon your work non-commercially.

Abbreviations:

GAVE: Gastric antral vascular ectasia; APC - Argon plasma coagulation; PHG: Portal hypertensive gastropathy; RBC: Red blood cells; TIVA:- Total intravenous anesthesia

Citation:

Vickovic S. Uncommon Cause of Gastrointestinal Bleeding. Ann Clin Med Case Rep. 2021; V5(12): 1-2

1. Introduction

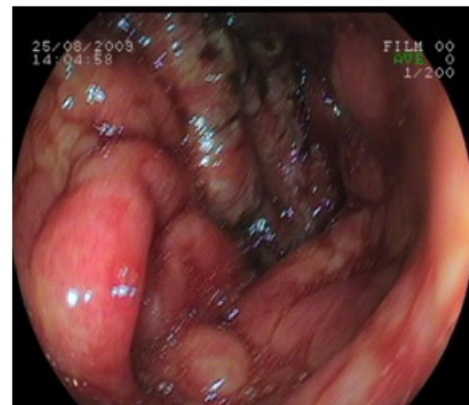Gastric antral vascular ectasia is an uncommon cause of chronic gastrointestinal bleeding or iron deficiency anaemia [1]. The condition is associated with dilated small blood vessels in the antrum, or the last part of the stomach. It is also called watermelon stomach because streaky long red areas that are present in the stomach may resemble the markings on watermelon [2]. GAVE is associated with a number of conditions, including portal hypertension, chronic renal failure and collagen vascular diseases particularly scleroderma. GAVE is treated with treatment through the endoscope, including argon plasma coagulation and electrocautery. Other medical treatments have been tried and include estrogen and progesterone therapy and anti-fibrinolytic drugs such as tranexamic acid.

2. Case Report

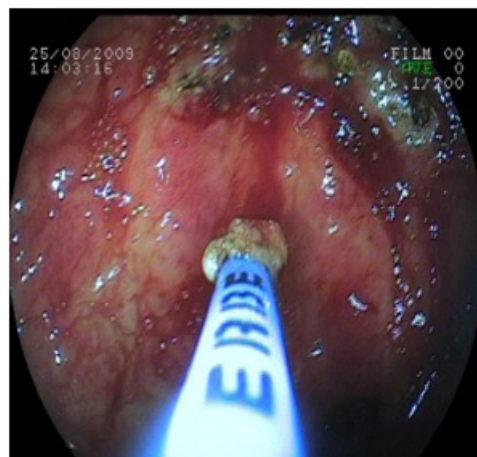
The 69 years old woman was first admitted to our Department due to severe gastrointestinal bleeding. In her previous history, she had tonsillectomy, cholecystectomy and heart failure. In laboratory analysis she had severe anemia. During upper gastrointestinal endoscopy in total intravenous anesthesia, the features of GAVE were apparent (Picture 1) We arranged access to argon plasma coagulation (Picture 2) With a total number of 7 sessions of APC, we managed to prolong the out-of-hospital periods and thereby somewhat decrease the RBC transfusion consumption. Tranexamic acid were included.

3. Discussion

Gastrointestinal endoscopic procedure has become an essential modality for evaluation and management of gastrointestinal tract abnormalities. The safe sedation (TIVA) of patients for this procedure requires a combination



Picture 1



Picture 2

of properly trained physicians and appropriate facilities. Moreover, proper selection and preparation of patients, suitable sedative technique, and application of drugs is essential. The use of short acting drug, adequate dose of sedative agents and sedation endpoint as well as appropriate sedation technique has an important role and also increased the safety [3, 4].

Gastric antral vascular ectasia was first described in a patient with severe chronic iron-deficiency anaemia. Gastroscopy showed a grey smooth mucosa of the corpus. In contrast, the antrum was reported to be hypertrophic mucosal changes, adherent old blood and scattered areas of profuse bleeding were also noted. Microscopy revealed a chronic inflammation and an oedematous submucosa with large, dilated veins. This condition was described as an erosive type of gastritis with marked veno-capillary ectasia. A more accurate definition defined GAVE as longitudinal antral folds converging on the pylorus, containing visible columns of tortuous red ectatic vessels. Histological appearances were described as hyperplasia of the mucosa with capillary ectasia and thrombosis, fibromuscular hyperplasia of the lamina propria and abnormal vessels in the submucosa. In accordance with the endoscopic appearance, which resembled the stripes on a watermelon, they dubbed the condition watermelon stomach.

GAVE is a rare entity, but is found in about 4% of all non-variceal upper gastrointestinal bleeding. The real incidence remains unknown as only symptomatic patients will undergo gastroscopy and then be diagnosed. Furthermore, the tendency to bleed is probably overestimated as most studies reporting on GAVE are subject to selection bias.

GAVE is usually found in patients suffering from severe co-morbidities like liver cirrhosis, autoimmune connective tissue diseases, chronic renal failure and bone marrow transplantation. Attempts should be made to identify any underlying co-morbidities, as treatment of these can lead to the resolution of GAVE. Despite the fact that only 30% of GAVE patients suffer from liver cirrhosis most studies have looked into this subgroup. A causal link between cirrhosis and GAVE seems likely as these patients have higher degrees of liver failure and liver transplantation can lead to resolution of GAVE. Portal hypertension, however, is unlikely to be important in the pathogenesis as there is a clear lack of response to measures reducing portal pressures. No model of how liver cirrhosis causes GAVE has been published to this day [5].

Two studies suggest a role for abnormal antral motility and physical stress on the mucosa. The evidence for all 4 of the above theories remains patchy and unconvincing. Most patients suffering from GAVE present with iron-deficiency anaemia, but few will have signs of acute upper gastrointestinal bleeding. The diagnosis will be made on endoscopy. If there is uncertainty whether mucosal abnormalities are due to PHG or GAVE, biopsies will help to distinguish between the 2 conditions. Making the right diagnosis in these cases is vitally important as PHG, in contrast to GAVE, will respond well to a reduction in portal pressures.

4. Conclusion

Treatment options for GAVE include endoscopic ablation (argon plasma coagulation), surgical antrectomy or pharmacological therapy with oestrogen (and / or progesterone), tranexamic acid or thalidomide.

References

1. Selinger CP, Ang YS. Gastric antral vascular ectasia (GAVE): an up-

date on clinical presentation, pathophysiology and treatment. *Digestion*. 2008; 77: 131-7.

2. Novitsky YW, Kercher KW, Czerniach DR, Litwin DE. Watermelon stomach: pathophysiology, diagnosis, and management. *J Gastrointest Surg*. 2003; 7: 652-61.
3. Amornyotin S. Intravenous Sedation Techniques for Gastrointestinal Endoscopy. *J Gastroenterol Hepatol Res* 2016; 5(3): 2050-57.
4. Amornyotin S. Sedative and analgesic drugs for gastrointestinal endoscopic procedure. *J Gastroenterol Hepatol Res* 2014; 3: 1133-1144.
5. Santosh Man Shresth. Medical management of Hepatic Vena Cava Syndrome. *Japanese Journal of Gastroenterology and Hepatology* 2019; 1: 1-9.