

## A Rare Case of Co-Infection with Pulmonary Tuberculosis and Palatal Actinomycosis

Saroach M<sup>1\*</sup>, Dadwal DS<sup>2</sup>, Grover R<sup>3</sup> and Saini A<sup>4</sup>

<sup>1</sup>Department of E.N.T, Dr.R.P.Govt.Medical College Kangra, HP, India

<sup>2</sup>Department of Chest & TB, Dr.R.P.Govt.Medical College Kangra HP, India

<sup>3</sup>Department of Head and neck surgeon, Medicaid Hospital Amritsar. Punjab, India

<sup>4</sup>Department of Otolaryngology, Dr.R.P.Govt.Medical College Kangra, HP, India

### \*Corresponding author:

Munish Kumar Saroch,  
Department of E.N.T, Dr.R.P.Govt.Medical  
College Kangra, HP, India,  
E-mail: drsaroach@gmail.com

Received: 10 Feb 2021

Accepted: 04 Mar 2021

Published: 06 Mar 2021

### Copyright:

©2021 Saroch M et al., This is an open access article distributed under the terms of the Creative Commons Attribution License, which permits unrestricted use, distribution, and build upon your work non-commercially.

### Citation:

Saroach M. A Rare Case of Co-Infection with Pulmonary Tuberculosis and Palatal Actinomycosis. Ann Clin Med Case Rep. 2021; V6(2): 1-3

### 1. Abstract

Palatal actinomycosis is an infection rarely described in literature, especially in the form of co-infection with pulmonary infection. We report a case of 55 year old male who reported in our O.P.D. with palatal fistula communicating oral cavity to nasal cavity. Patient had nasal regurgitation of food and when history in detail was taken he reported that he had taken complete course of ATT for 6 months. The biopsy was taken from palatal fistula was consistent with actinomycosis. The patient has fully recovered from tuberculosis and now under treatment for actinomycosis. We also present a brief review of literature as well as a full description and discussion of this case

### 2. Introduction

Actinomycosis is a chronic suppurative bacterial infection characterised by multiple abscesses, fistulous pathways and fibrosis involving face, neck, chest and abdomen. It is caused by Actinomyces spp. a group of anaerobic gram-positive saprophytic bacteria. We present a rare case of palatal fistula who had already completed course of ATT. He was being sputum positive [1]. On HPE of palatal site it came out Actinomyces spp. Infection.

### 3. Case Report

A 55 year old tibetian male from chauntra monastery area, shopkeeper by profession reported in E.N.T. O.P.D. with nasal regurgitation. He gave the h/o being taken a complete course of ATT for 6

months. Before starting ATT he was AFB +ve. He was not known diabetic, alcoholic & was nonsmoker. The examination of oral cavity revealed an ulcerous lesion of the palate, suggesting fistulous communication of oral and nasal cavities. CT scans of the head revealed a large osteolytic lesion in the hard palate. Aerobic, anaerobic and AFB cultures of the lesions were negative. The histological examination of the lesion revealed fragments of inflamed mucosa and dead bone with bacterial colonies, consistent with actinomycosis no tuberculoid granuloma or evidence of malignancy seen [2].

#### 3.1 General Physical Examination

- Vitals---- WNL
- Pallor/cyanosis/jaundice/oedema/clubbing: negative

#### 3.2. E.N.T. Examination

##### a) Neck /Throat/Larynx

- Oral cavity proper---tongue –wnl
- floor of mouth—wnl
- cheek mucosa—wnl
- palate-there is fistulous communication between oral cavity proper and nasal cavity.
- oropharynx-----wnl
- indirect laryngoscopy---wnl
- neck area for secondaries etc. ---wnl

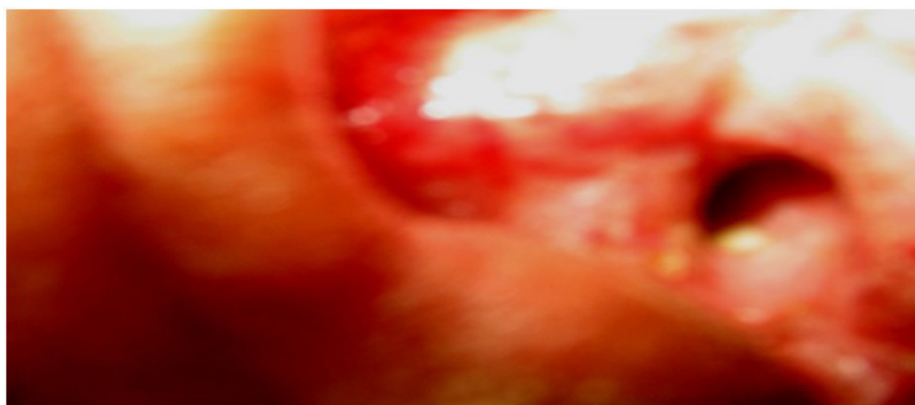
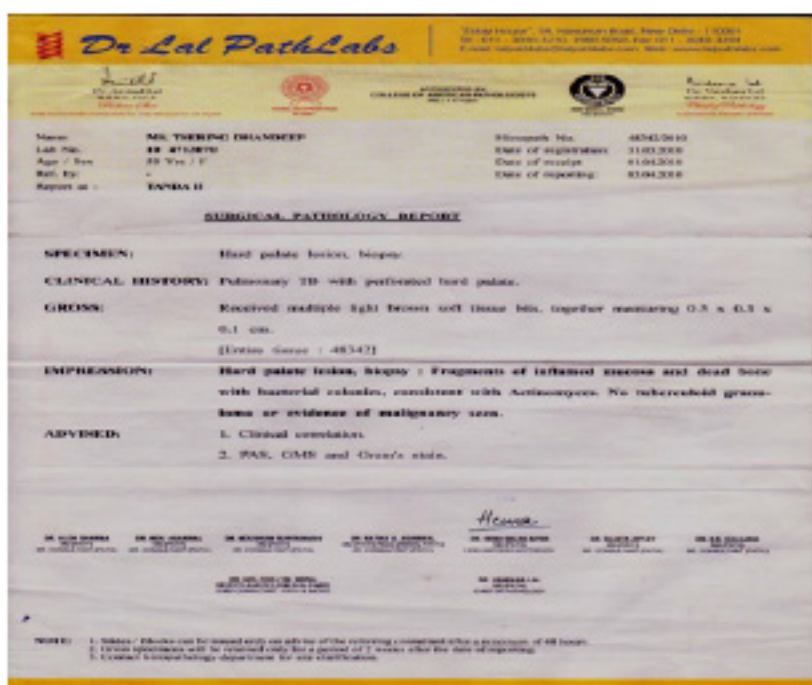


Figure (i) showing palatal perforation.

Attached



b)Ear-----wnl

c)Nose/PNS/Nasopharynx----wnl

**4. Investigations**

a)Haemogramme WNL

b)Biochemistry WNL

c)Histopathology

**5. Treatment**

- Medical Care The presence of associated bacteria in actinomycosis appears to be fundamental to the development of clinical infection. Therefore, antibiotic coverage should be aimed at all associated organisms in patients with actinomycosis. An aerobic environment is an unfavorable condition for the growth of Actinomyces species and thus halts the infection.

- With the combination of administering penicillin therapy and creating an aerobic environment with surgery, cure has become the rule rather than the exception.
- The treatment of choice for actinomycosis includes large doses of antibiotics and prolonged therapy coupled with drainage of the abscesses or radical excision of the sinus tracts. High penicillin concentrations are necessary to penetrate areas of fibrosis and suppuration and possibly the granules themselves. Occasionally, extensive actinomycosis may respond to intravenous penicillin alone, rendering surgery unnecessary
- Actinomyces organisms are also susceptible to chloramphenicol, erythromycin, tetracyclines, and clindamycin but not to metronidazole or aminoglycosides. This patient was put on higher doses of penicillin intravenously & later on he was put on erythromycin. Still he is under our

treatment and visiting our O.P.D. He is in the final stages of healing of palatal fistulous communicatio

### 5.1 Surgical Care

- Surgical management in actinomycosis has consisted of various treatment modalities, including excision of sinus tracts, drainage of the abscess cavities, removal of the bulky infected masses, and irrigation and curettage of the osteomyelitic bony lesions [3].
- The abscesses of actinomycosis should be drained, or sinus tracts should be radically excised. With the combined use of penicillin and surgery, cure has become the rule rather than the exception.

### 6. Discussion

- *Actinomyces* spp. are anaerobic or aerotolerant (facultatively anaerobic), non-sporulating, gram-positive bacteria that tend to form branching rods and filaments and have a fermentative type of carbohydrate metabolism.
- *Actinomyces* spp. are commensals of the mouth cavity and the upper respiratory tract. Their presence in the oral and respiratory specimens does not necessarily signify clinical disease and might often not be reported. In our case and in other cases described in the literature, a significant disease process was identified. We postulate that preexisting periodontal disease was the source of infecti The pulmonary infection by *M. tuberculosis* was acquired by epidemiologic factors. Most infections with *Actinomyces* spp. are polymicrobial. The copathogens are most commonly colonizers of the respective involved organ systems. They act synergistically by inhibiting host defense mechanisms or reducing the oxygen tension in the affected tissue, which promotes the growth of *Actinomyces* spp [4].

For the treatment of actinomycosis, the antibiotic of choice is penicillin, as shown in the majority of international guidelines. In this specific case, the antibiotic should have been administered orally in severe or rapidly progressive cases, penicillin administration should be initiated intravenously. Other antibiotics (ampicillin, tetracycline and clindamycin) can be used orally with good treatment results. Due to the strong tendency toward recurrence of this infectious agent, the treatment should be extended to 6-12 months [5].

- In the literature, we found no reports of tuberculosis patients co-infected with *A. naeslundii*.
- Resistance to antimycobacterial drugs is a common cause of therapeutic failure of tuberculosis. In the setting of full susceptibility, other entities such as a co-infection might be suspected and appropriate cultures obtained. The *M. tuberculosis* and *Actinomyces* spp. co-infection is rare and therefore presents a diagnostic challenge in clinical

practice. Early identification prevents prolonged diagnostic and therapeutic interventions that increase health care costs.

### Reference

1. Ferreira Dde F, Amado J, Neves S, Taveira N, Carvalho A, Nogueira R. Treatment of pulmonary actinomycosis with levofloxacin. *J Bras Pneumol.* 2008; 34(4): 245-8.
2. Tietz A, Aldridge KE, Figueroa JE. Disseminated coinfection with *Actinomyces graevenitzii* and *Mycobacterium tuberculosis*: case report and review of the literature. *J Clin Microbiol.* 2005; 43(6): 3017-22.
3. Mabeza GF, Macfarlane J. Pulmonary actinomycosis. *Eur Respir J.* 2003;21(3):545-51.
4. Russo TA. Agents of actinomycosis. In: Mandell GL, Douglas RG, Bennett JE, Dolin R, editors. *Principles and practices of infectious diseases.* Philadelphia: Churchill Livingstone; 2000: p. 2645-54.
5. Fishman, J. Approach to the Patient with Pulmonary Infection, In: Fishman AP, Elias JA, Fishman JA, Grippi MA, Senior RM, Pack AI, editors. *Fishman's Manual of Pulmonary Diseases and Disorders.* New York: McGraw-Hill; 2008. p. 1981-2015.