

## Asymptomatic Right Atrial Lipoma in A 42-Year-Old Patient : A Case Report

Hong-ji Z<sup>1</sup>, Wei W<sup>1\*</sup>, Mei-mei J<sup>2</sup> and Fei L<sup>3</sup>

<sup>1</sup>Department of Radiology, the First Affiliated Hospital of University of Science and Technology of China, Hefei 230001, Anhui Province, China

<sup>2</sup>Department of Ultrasound Medicine, the Committee Hospital of Anhui Provincial Party, Hefei 230001, Anhui Province, China

<sup>3</sup>Department of Cardiac Surgery, the First Affiliated Hospital of University of Science and Technology of China, Hefei 230001, Anhui Province, China

### \*Corresponding author:

Wei Wei,

Department of Radiology, the First  
Affiliated Hospital of University of Science and  
Technology of China, Hefei 230001,  
Anhui Province, China,  
E-mail: weiweill@126.com

Received: 04 Apr 2021

Accepted: 21 Apr 2021

Published: 26 Apr 2021

### Copyright:

©2021 Wei W. This is an open access article distributed under the terms of the Creative Commons Attribution License, which permits unrestricted use, distribution, and build upon your work non-commercially.

### Citation:

Wei W. Asymptomatic Right Atrial Lipoma in A 42-Year-Old Patient : A Case Report. *Ann Clin Med Case Rep.* 2021; V6(12): 1-3.

### Keywords:

Asymptomatic heart lipoma

### 1. Abstract

Lipoma, a common soft tissue tumor composed of mature adipose tissues, can occur in any part of the body with fat. Accounting for 8.4% of primary heart tumors [1], the lipoma in the heart is rare, and the most common sites are the right atrium, left ventricle, and pericardium [2,3]. Most patients with cardiac lipomas have no symptoms, and some may experience palpitations, syncope, or even cardiac arrest [4, 5].

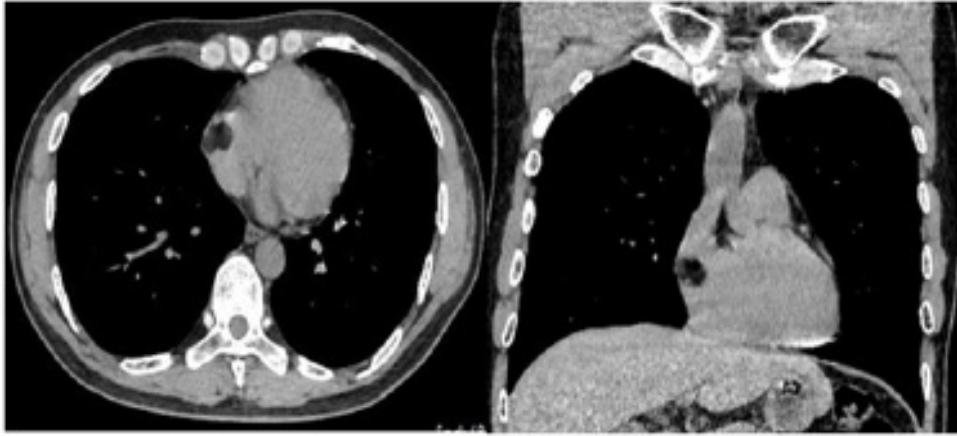
### 2. Introduction

Because the incidence of cardiac lipoma is low and the symptoms are not obvious in some patients, the specificity of clinical and laboratory examinations is low, and it is easy to be missed. Imaging examinations have good diagnostic value for cardiac tumors. The most commonly-used clinical examination is echocardiography and MDCT [6,7], which has a high diagnostic value in determining lipoma's location, size, range of motion and its relationship with surrounding structures [8]. MDCT can make the diagnosis of lipoma easier because the CT value of fat density provides great help in diagnosing the qualitative disease.

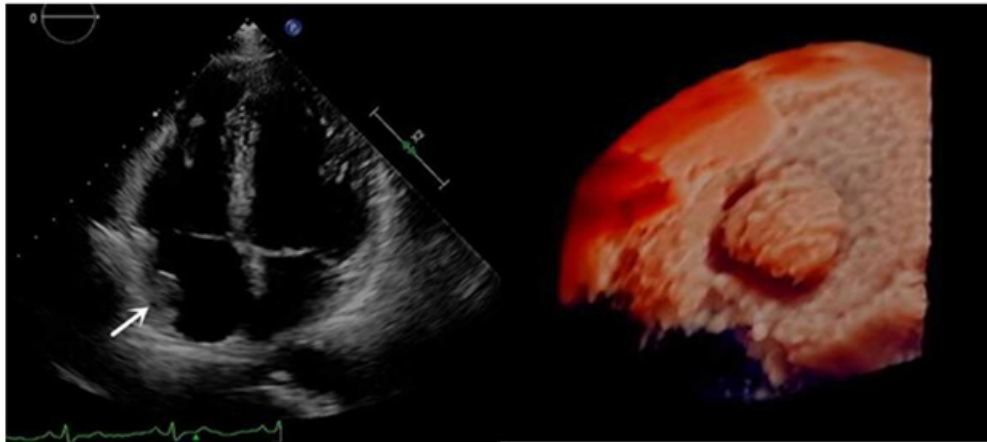
### 3. Case Presentation

A 42-year-old man was found to have a right atrium occupation

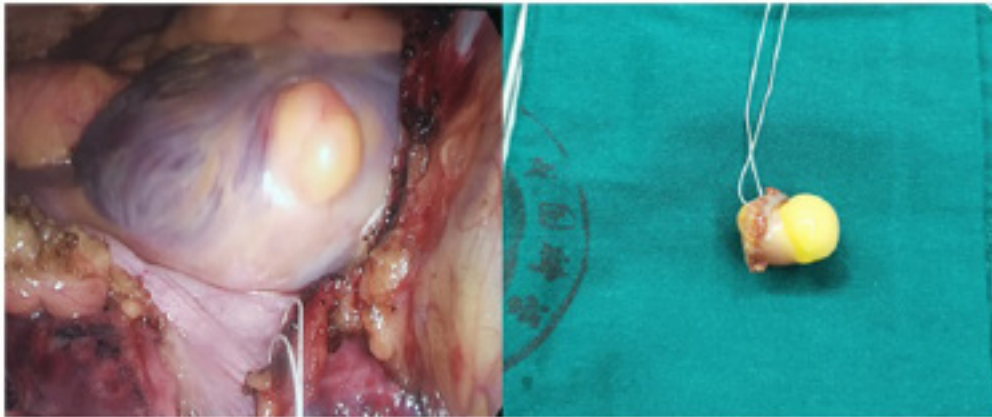
during routine physical examination. Admission physical examination: clear mind, normal spirit, no cyanosis of the lips, clubbing (-), slightly thicker lung breath sounds, heart rate 75 beats/min, regular rhythm, no heart murmur or pericardial friction, and no edema. Ordinary electrocardiogram: sinus rhythm. CT: massive low-density shadow sized 2.0cm×1.5cm in the right atrium with clear boundary and irregular shape; the CT value was about -110HU (Figure 1). Real-time three-dimensional transesophageal echocardiography: a clump-like echo sized 2.1cm×1.6cm on the posterior wall of the right atrium, with a wide base, uniform internal echo, smooth edge, and slight swing. No obvious clump-like echo attachment was found in the left atrium and auricle (Figure 2). Diagnosis: occupation of right atrium. Surgery: general anesthesia with cardiopulmonary bypass and total thoracoscopic cardiac mass resection with atrial repair. During the surgery, the tumor pedicle, about 1.5cm in diameter, was found located in the middle of the right atrium with a 1-cm distance from the atrioventricular groove, and the tumor, with smooth surface and tough texture, was about 2cm×3cm in size (Figure 3). Pathology: A mature adipose tissue tumor-like hyperplasia was seen under the microscope, with a thin envelope on the edge, and a small amount of myocardial tissue around it, consistent with the characteristics of a lipoma (Figure 4).



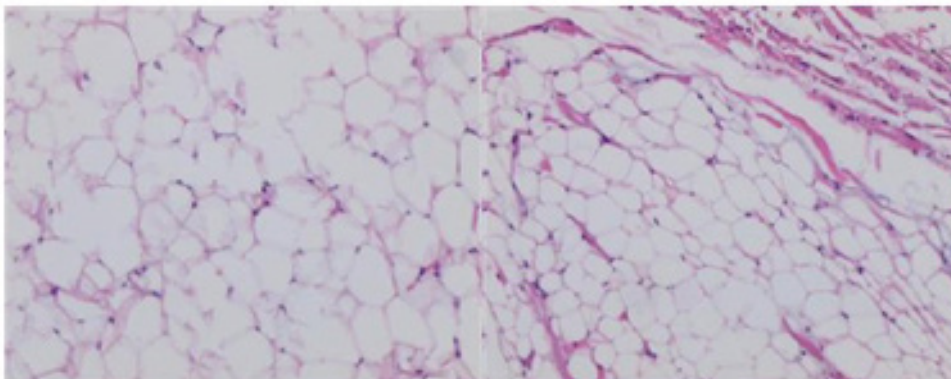
**Figure 1:** CT showed a massive low-density shadow in the right atrium (2.0cm×1.5cm).



**Figure 2:** Echocardiography showed a clumpy echo in the posterior wall of the atrium.



**Figure 3:** The tumor pedicle was found in the middle of the right atrium during the operation.



**Figure 4:** Microscopic findings of the right atrium lipoma showed tumorous hyperplasia of mature adipose tissues (original magnification, ×100 (left) ×400 (right)).

#### 4. Discussion

Since the conventional chest CT lung window cannot show the lesions in asymptomatic patients like this case, a suitable mediastinal window can be of great help in showing the lesions of cardiac lipoma. In addition, the conventional transverse position can be adopted for easy comparison between the lesion and the normal surrounding part of the heart. Fat obfuscation requires the multi-planar reconstruction technology. Enhanced scanning can improve the accuracy of diagnosis and further avoid missed diagnosis or misdiagnosis. Currently, guidelines for the treatment of cardiac lipomas are not available. Most patients receive radical resection to relieve the symptoms caused by cardiac lipomas. Although conservative treatment can be adopted for asymptomatic cardiac lipomas, the lipomas may overgrow and infiltrate the myocardium, leading to undesirable results [9, 10]. Therefore, all patients with cardiac lipomas should be closely followed up using imaging methods to monitor the changes of lipomas.

#### Reference

1. Ismail Imtiaz, Al-Khafaji Khalid, Mutyala Monica, Aggarwal S, Cotter W, Hakim H, et al. Cardiac lipoma. *J Community Hosp Intern Med Perspect*. 2015; 5(5): 28449.
2. Fan S, Guo H. The imaging features of cardiac lipoma. *Chinese Journal of Clinical Thoracic and Cardiovascular Surgery*. 2019; 26(6): 606-610.
3. Gulmez O, Pehlivanoglu S, Turkoz R, Demiralay E, Gumus B. Lipoma of the right atrium. *J Clin Ultrasound*. 2009; 37 (3): 185-188.
4. Abdelradi Amr, Yekta Arshad. A Case of Asymptomatic Cardiac Lipoma and Literature Review. 2020; 10: 002.
5. Wang H, Hu J, Sun X, Wang P, Du Z. An asymptomatic right atrial in-tramycardial lipoma: a management dilemma. *World J Surg Oncol*. 2015; 13: 20.
6. Barbuto L, Ponsiglione A, Del Vecchio W, Altiero M, Rossi G, Rosa DD, et al. Humongous right atrial lipoma: A correlative CT and MR case report. *Quant Imaging Med Surg*. 2015; 5(5): 774-777.
7. Liu L, Zuo Y, Huang Y, Cao L. Echocardiographic findings of giant cardiac lipoma: A case report. 2019; 98(8): e14456-e14456.
8. Gırrbach F, Mohr FW, Misfeld M. Epicardial lipoma-a rare differential diagnosis in cardiovascular medicine. *Eur J Cardiothorac Surg*. 2012; 41(3): 699-701.
9. Shu S, Wang J, Zheng C. From pathogenesis to treatment, a systemic review of cardiac lipoma. *J Cardiothorac Surg*. 2021;16(1):1-7.
10. Elbardissi AW, Dearani JA, Daly RC, Mullany CJ, Orszulak TA, Puga FJ, et al. Survival after resection of primary cardiac tumors: a 48-year experience. *Circulation*. 2008; 118(14): S7-15.