

## Conservative Treatment of Retained Placentas: A Report of Two Cases

Xiaotong Tang<sup>1</sup>, Yuanyuan Zhu<sup>1</sup>, Dan Wu<sup>2\*</sup> and Lizhou Sun<sup>1\*</sup>

<sup>1</sup>Department of Obstetrics and Gynecology, The First Affiliated Hospital of Nanjing Medical University, Nanjing, Jiangsu, China

<sup>2</sup>Department of Obstetrics and Gynecology, Women's Hospital of Nanjing Medical University Nanjing Maternity and Child Health Care Hospital 123 Tianfeixiang, Mochou Road, Qinhuai District Nanjing 210004, China

### \*Corresponding author:

Dan Wu & Lizhou Sun,  
Department of Obstetrics and Gynecology,  
Women's Hospital of Nanjing Medical University,  
Nanjing Maternity and Child Health Care  
Hospital, 123 Tianfeixiang, Mochou Road,  
Qinhuai District, Nanjing 210004, Department  
of Obstetrics and Gynecology, The First Affiliated  
Hospital of Nanjing Medical University, 300  
Guangzhou road, Gulou District, Nanjing City,  
Jiangsu Province, China, Tel. +86 13605171213,  
E-mail: lizhou\_sun@163.com

Received: 04 Mar 2022

Accepted: 19 Mar 2022

Published: 23 Mar 2022

J Short Name: ACMCR

### Copyright:

©2022 Dan Wu and lizhou Sun. This is an open access article distributed under the terms of the Creative Commons Attribution License, which permits unrestricted use, distribution, and build upon your work non-commercially.

### Citation:

Dan Wu and lizhou Sun, Conservative Treatment of Retained Placentas: A Report of Two Cases. Ann Clin Med Case Rep. 2022; V8(16): 1-6

### Keywords:

Placenta accrete; Conservation treatment; Methotrexate; Uterine artery embolization

## 1. Summary

**What is known and objective:** To demonstrate conservative treatments for retained placenta accreta in puerperants who underwent induced labour of dead fetuses in the second trimester.

**Case summaries:** In this retrospective study, two patients who underwent induced labour of dead fetuses in the second trimester showed retained placenta accreta, typically managed by surgical and conservative treatments. We address conservative treatments, including drug therapy, methotrexate, and uterine artery embolism.

**What is new and conclusion:** In both cases, the placenta remaining in the uterine cavity was discharged smoothly without vaginal haemorrhage. Thus, conservative treatment is effective for placenta accreta and fertility retention.

## 2. What Is Known and Objective

Placenta accreta refers to the invasion of placental tissue into the myometrium of the uterus in varying degrees [1], which is classified into three types: placenta accreta, placenta increta, and placenta percreta [2]. Placenta accreta can cause a retained placenta, with or without vaginal bleeding. In the clinic, it is easy to cause uterine contraction, puerperal infection, postpartum haemorrhage, haemorrhagic shock, and even hysterectomy [3]. However, the pathogenesis of placental accreta remains unclear. It is generally believed that placental accreta is related to decidual loss, increased invasiveness of trophoblasts, and abnormal remodelling of the uterine spiral artery. These factors interact and influence each other, leading to the formation of placental accrete [4-5]. In the

prenatal stage, clinicians usually combine the clear risk factors and imaging data to ensure reasonable doubt and preoperative preparation for placental accreta. The high-risk factors include the age of the parturient, history of uterine operation, types of placenta previa, history of caesarean section, and an abnormal uterine structure [6]. In addition, clinicians evaluate the degree of placental accreta by type B ultrasound (B-US)-related characteristics, such as placental position, placental thickness, continuity of the hypoechoic zone, continuity of the bladder line, placental lacuna, blood flow at the base of the placenta, and cervical morphology [7]. Currently, the management of placenta accreta includes surgical and conservative treatments. In this article, we describe two cases to clarify the effectiveness of conservative treatments on placenta accrete [8].

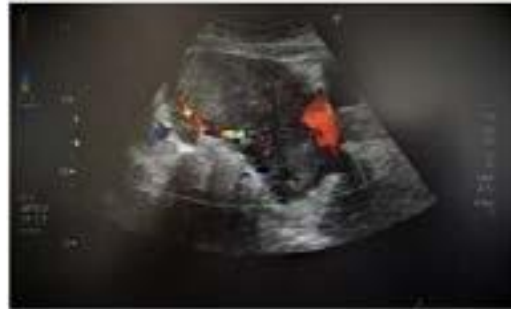## 3. Case Summaries

### Case 1

A 30-year-old puerpera was induced due to intrauterine foetal death in another hospital on March 29<sup>th</sup>. One day later, she gave birth to a dead baby girl, but placenta retention occurred and manual removal failed. Therefore, the patient was urgently transferred to a superior hospital. On admission, human chorionic gonadotropin (HCG) levels of the puerperant reached 8196.5 IU/L, and C-reactive protein (CRP) levels increased obviously. B-US showed a retained placenta (size: 74 × 67 × 47 mm) and placenta accreta (Figure 1). As the patient had no symptoms of vaginal haemorrhage, the patient was managed conservatively: oral mifepristone (50 mg twice daily) and intravenous oxytocin (40 U) to

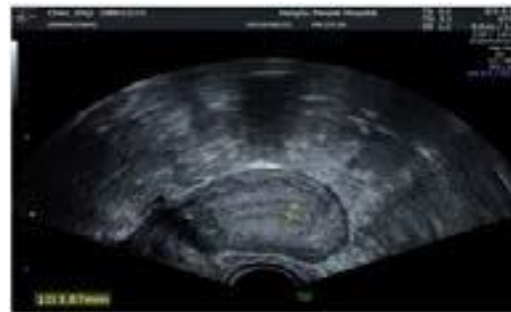
promote uterine contraction, combined with motherwort herb and quinolone anti-infection treatment. In this process, some relevant indices such as CRP, procalcitonin (PCT), and HCG fluctuations were monitored dynamically by clinicians (Table 1). In addition, B-US examination was performed every two weeks to evaluate the treatment efficacy. As the patient had no obvious symptoms, she required discharge from the hospital on the 22<sup>nd</sup> April and followed

up in the outpatient department. During outpatient follow-up, the patient continued to take motherwort herb orally. The placenta was delivered from the vagina on the 8<sup>th</sup> day after discharge, and HCG levels gradually returned to normal. After almost two months, no abnormality was found in the B-US examination in the outpatient department (Figure 2).



**Figure 1:** B-ultrasound (April 1st).

1. The size of the placenta was 74\*67\*47 mm in the uterine cavity.
2. CDFI detected plenty of blood flow signals after the placenta CDFI, Colour Doppler Flow Imaging



**Figure 2:** B-ultrasound (June 21<sup>st</sup>).

1. The size of the uterus returned to normal.
2. Endometrial thickness was 3.9 mm.
3. No obvious abnormality of the uterine appendage.

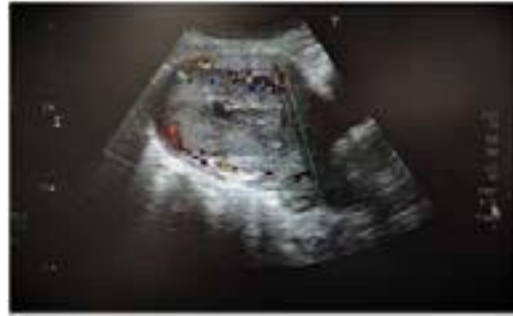**Table 1:** Fluctuations in HCG and CRP levels in blood during hospitalization and outpatient follow-up.

	March 31st	April 3rd	April 8th	April 11th	April 15th	April 18th	April 22nd	May 10th	June 21st
CRP (mg/L)	123	38	9	/	8	/	/	/	/
HCG (IU/L)	8196.5	9799.0	5292.0	3147.0	1670.3	815.1	543.7	27.6	0.5

**Case 2**

A 26-year-old puerperant underwent induced labour due to intra-uterine foetal death on May 10<sup>th</sup>. Two days later, she gave birth to a dead baby boy, and the placenta was retained, and B-US examination demonstrated placenta accreta. On May 21<sup>st</sup>, the patient was transferred to a superior hospital. On admission, the HCG level reached 1380.9 IU/L. B-US showed a retained placenta (size: 84 × 54 mm) and placenta accreta (Figure 3). As no obvious signs of bleeding were observed, the patient was treated with conservative treatments, including oral mifepristone (50 mg twice daily) and intramuscular injection of oxytocin to promote uterine contraction, combined with oral motherwort herb to promote uterine involution and cephalosporin anti-infection treatment. In this process, dynamic changes of relevant indices such as CRP, PCT, and HCG (Table 2) fluctuations were monitored by attending doctors. In addition,

regular examination was also used to observe intrauterine changes. As the patient had no obvious symptoms, she was discharged from the hospital on June 3<sup>rd</sup> and was followed up in the outpatient department. After discharge, she continued to take oral mifepristone (50 mg). However, the parturient was admitted to the hospital again for infectious fever, and the patient was given quinolones for anti-infection treatments. After five days, the inflammatory index decreased significantly, and HCG levels returned to normal. B-US indicated that placental blood flow decreased significantly (Figure 4). Therefore, complete curettage of the uterine cavity was performed the next day. After the operation, oxytocin and motherwort herb were continued. Six days later, this patient was discharged and was followed up in the outpatient department. After almost two months, no abnormality was found in the B-US examination in the outpatient department (Figure 5).

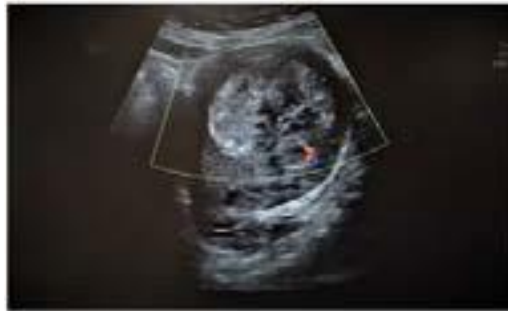

**Figure 3:** B-ultrasound (May 21<sup>st</sup>).

1. The size of the placenta was 84\*54 mm in the uterine cavity.
2. CDFI detected plenty of blood flow signals after the placenta

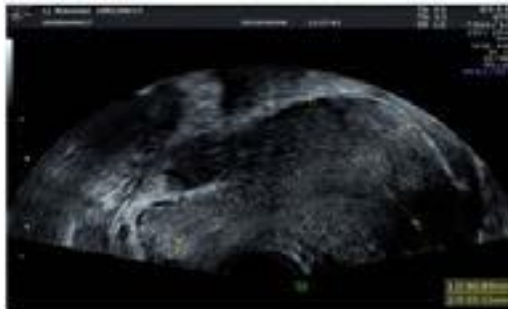**Table 2:** Fluctuations in HCG and CRP levels in blood during hospitalization and outpatient follow-up.

	May 21st	May 23rd	May 27th	May 30th	June 3rd	June 7th	June 21st	June 28th	July 5th	July 11th	July 16th
CRP (mg/L)	25	27	20	/	14	/	/	/	/	134	55
HCG (IU/L)	1380.9	788.6	474.0	312.4	135.9	109.9	69.1	64.1	46.8	28.5	2.8



**Figure 4:** B-ultrasound (July 21<sup>st</sup>).

1. The size of the placenta was 60\*47\*64 mm in the uterine cavity.
2. CDFI detected little blood flow signals after the placenta.



**Figure 5:** B-ultrasound (Sept. 16<sup>th</sup>)

1. The size of the uterus returned to normal.
2. Endometrial thickness was 14.8 mm with an unequal echo.
3. No obvious abnormality of the uterine appendage.

#### 4. Discussion

Placenta accreta is the main cause of a retained placenta, which can lead to severe vaginal haemorrhage. The treatment methods are dependent on the symptoms present. The different treatments are divided into two categories: surgical and conservative. In this article, we mainly explore the role of conservative treatments in retained placenta accreta. The indications for conservative treatment usually include the following points. First, patients with stable vital signs, no active vaginal bleeding, normal liver and kidney function, fertility requirements, and no infection tendencies. Second, patients who try conservative treatments should understand the limitations and complications involved. Before administering conservative treatment, superior hospitals should have corresponding rescue measures, such as timely blood transfusion, emergency hysterectomy, highly effective antibiotics, and regular B-US monitoring, and  $\beta$ -HCG detection [9,10]. In order to reduce the blood supply to the placenta and inhibit the activity of the chorionic villi cells, we usually adopt treatments for placenta *in situ* preservation, such as oral administration of mifepristone, methotrexate, and uterine artery chemoembolization.

##### Mifepristone

Mifepristone is a typical anti-progestin, which usually acts on the decidual tissue and chorion. Its main mechanism is to combine with the progesterone receptor to inhibit the secretion of progesterone and promote oedema, deformation, necrosis, and apoptosis of the decidual tissue as well as enema of the chorion, which is conducive to the stripping of the foetal membrane and placenta, softening and expanding the cervix, promoting the decomposition of cervical collagen, inhibiting synthesis, and enhancing uterine contraction [11]. Meanwhile, its anti-glucocorticoid activity can stimulate the decidual cytotoxic activity that is mediated by the natural killer cells of the uterus, leading to partial autolysis of the placenta. In addition, it is helpful for cervical dilatation and contraction of the uterus. After one hour of oral mifepristone, the blood concentration reaches a peak, and its half-life period is 20-25 hours without accumulation [12]. Therefore, the mifepristone dosing regimen is 50 mg twice daily, which can maintain a high blood concentration in the body for 24 h, leading to good therapeutic effects [13].

##### Methotrexate (MTX)

MTX is an antifolate, which is often used as an antitumor agent and mainly inhibits the growth and reproduction of tumour cells by inhibiting the synthesis of DNA [14]. Based on the theory that the activity of trophoblast division and synthesis is similar to that in tumours, MTX is usually used in the conservative treatment of placenta accreta, leading to the obstruction of trophoblast synthesis [15]. Finally, MTX causes the villus cells in the implanted site to degenerate, necrose, and fall off. MTX can be administered intravenously or locally. First, MTX chemotherapy (1 mg/kg) by intra-

muscular injection usually requires a 6-day course. Intramuscular injection of MTX is on the 1st, 3rd, and 5th day of the treatment regimen while folic acid is administered on the 2nd, 4th, and 6th day, with a 10–20% dose of MTX to reduce the toxicity of MTX. If the patient's response to MTX is not sufficient (no significant decrease of HCG), another course of treatment can be administered, but the interval between the two courses should be at least two weeks [16]. Generally, this method has large side effects, such as liver function damage, bone marrow inhibition, gastrointestinal reactions, stomatitis, and other side effects, and due to the first-pass effect of the liver, the drug effect is diminished. Therefore, topical use can be used to increase efficacy [17]. Second, topical use of MTX into the placental tissue can avoid the first-pass effect of the liver and the disadvantages of low drug concentrations in the uterus, small dosages, and long durations of medication. On the other hand, the local tissue can maintain a high concentration of MTX, improve the treatment effects, significantly shorten the treatment time, and reduce the corresponding side effects. During this treatment period, under B-US guidance, the 22G PTC puncture needle is used to puncture the placental tissue through the abdomen or vagina. After injecting one part, it changes its direction to another part of the placenta for another injection, so MTX (75 mg diluted with 20 mL normal saline) is injected in multiple directions. If the decrease in HCG is not ideal, the injection can be repeated every week [18]. Another treatment is usually associated with uterine artery embolization. With the assistance of radiation, the artery catheter was placed retrogradely in the uterine artery, a single dose of MTX (50 mg/m<sup>2</sup>) was infused into the uterine artery through the catheter, and embolization was performed with an embolic agent for stabilization. If needed, the artery catheter can be fixed for further embolization [19]. Generally, 3-10 days after the intervention, the blood supply to the placenta is monitored by B-US, and clinicians determine the next treatment plan according to the patient's condition and the changes in blood supply of the placenta. During pregnancy, the uterus has abundant collateral circulation, and a new blood supply can be established in a short time. In principle, the injury to the uterus is small. The selected embolic agents are mostly sponge gelatine, which is absorbed 14-21 days later. Therefore, for pregnant women with placenta accreta, uterine artery chemoembolization has the following advantages. First, it can significantly improve the blood concentration of MTX in the placenta, which can lead to the degeneration, edema, necrosis, and bleeding of the chorion and decidua tissue and cause their separation, contributing to the natural expulsion of the placental tissue. Second, uterine artery embolization can quickly control and block active vaginal bleeding to achieve haemostasis and improve the curative effects. Third, the best time for complete curettage of the uterine cavity is 24-72 hours after embolization, avoiding the risk of massive bleeding. Most importantly, for those who have fertility requirements, it is a safe method to retain the uterus and fertility [20].

## Traditional Chinese medicine

Traditional Chinese medicine usually plays an auxiliary role in the treatment of placenta accreta. For example, motherwort herb, the main components of which are prehispanolone and leonurine hydrochloride, can play a role in uterine contractions. Motherwort herbs play a role similar to that of pituitrin, which can improve uterine tension, promote uterine contraction, and increase the degree of excitement [21]. In addition, some other traditional Chinese medicines can promote blood circulation and remove blood stasis. When it is used in placenta accreta, it can promote thrombus shedding of the endometrium and reconstruction of the new endometrium. Through the above conservative treatments, most patients with placenta accreta can significantly alleviate their symptoms, and the placenta can be removed smoothly from the uterine wall with minimal harm. During the treatments, the changes in HCG, CRP, and PCT should be closely monitored. Generally, HCG should be retested once every three days, and the patient's body temperature and CRP and PCT levels should be measured regularly [22]. If necessary, vaginal secretions should be taken for culture. The changes in the residual placental tissue in the uterine cavity should be regularly monitored by B-US with careful attention to the changes in blood flow between the placenta and uterine wall, in order to determine the appropriate time to clear the uterus. In this study, two cases of placenta accreta were treated conservatively. In this study, two cases underwent induced labour due to intrauterine stillbirth. While both placentas were retained over 30 minutes after delivery, B-US suggested placenta accreta and CDFI detected an abundant blood supply to the placenta. At this time, if the patient's vaginal bleeding is not high and vital signs are stable, complete curettage of the uterine cavity will cause severe vaginal bleeding under B-US guidance, so the risk of emergency uterine artery embolization or even hysterectomy will increase. Based on the general stability of the patients in the two cases, mifepristone (50 mg twice daily), an oral anti-progesterone drug, supplemented with oxytocin to promote uterine contraction was preferred, and also promoted uterine involution and efficient anti-infection treatment. During the disease, the serum level of HCG was rechecked once every three days, while blood CRP and temperature changes were monitored regularly. In the two cases, HCG decreased steadily, and B-US indicated that the blood supply of the placenta decreased significantly. In case 1, the retained placental tissue was delivered by itself during the outpatient follow-up. Meanwhile, the patient had no signs of infection and HCG returned to normal. In case 2, the parturient had infection symptoms, and the vaginal secretion culture indicated bacterial infection. Considering that the HCG level returned to normal, B-US indicated that the blood supply of the placenta was significantly reduced. Furthermore, to avoid reoccurrence of intrauterine infection, it was important to confirm the appropriate timing for complete curettage of the uterine cavity. Therefore, when inflammation was under control,

clinicians performed the operation under the guidance of B-US to reduce haemorrhage. After the operation, motherwort herb was administered to promote uterine involution, and oxytocin was administered to promote contraction of the uterus. One month after discharge, B-US reexamination indicated that the uterus and menstruation were normal.

## 5. What is New and Conclusion

Placental accreta is one of the most challenging diseases in obstetrics. Obstetricians continue to explore new treatments to reduce uterine bleeding, retain maternal reproductive function, and reduce maternal mortality. Among them, the application of expectant treatment in placenta accreta has clinical significance, especially for women who have not given birth or who have fertility requirements in the future. However, the effect of conservative treatment is not ideal for placentas with an extensive implantation area and deep myometrium.

## 6. Funding

The work was supported by National Natural Science Foundation of China [82101781] and Project of Nanjing postdoctoral research [2021BSH207]

## References

1. Silver RM and DW. Branch, Placenta Accreta Spectrum. *N Engl J Med.* 2018; 378(16): p. 1529-1536.
2. Cramer SF and DS Heller, Placenta Accreta and Placenta Increta: An Approach to Pathogenesis Based on the Trophoblastic Differentiation Pathway. *Pediatr Dev Pathol.* 2016; 19(4): p. 320-33.
3. Jauniaux E S. Collins and GJ. Burton, Placenta accreta spectrum: pathophysiology and evidence-based anatomy for prenatal ultrasound imaging. *Am J Obstet Gynecol.* 2018; 218(1): p. 75-87.
4. Hannon T. Effects of local decidua on trophoblast invasion and spiral artery remodeling in focal placenta creta - an immunohistochemical study. *Placenta.* 2012; 33(12): p. 998-1004.
5. Duzjy CM. Extravillous trophoblast invasion in placenta accreta is associated with differential local expression of angiogenic and growth factors: a cross-sectional study. *BJOG.* 2018; 125(11): p. 1441-1448.
6. Rac MW. Ultrasound predictors of placental invasion: The Placenta Accreta Index. *Am J Obstet Gynecol.* 2015; 212(3): p. 343.e1-7.
7. Bourgioti C. MRI prognosticators for adverse maternal and neonatal clinical outcome in patients at high risk for placenta accreta spectrum (PAS) disorders. *J Magn Reson Imaging.* 2019; 50(2): p. 602-618.
8. Ou J. Management of patients with placenta accreta spectrum disorders who underwent pregnancy terminations in the second trimester: A retrospective study. *Eur J Obstet Gynecol Reprod Biol.* 2019; 242: p. 109-113.
9. Yu M. Diagnosis and treatment of placenta accreta in the second trimester of pregnancy]. *Zhongguo Yi Xue Ke Xue Yuan Xue Bao.* 2010; 32(5): p. 501-4.

10. Sentilhes L, G Kayem and RM. Silver, Conservative Management of Placenta Accreta Spectrum. *Clin Obstet Gynecol.* 2018; 61(4): p. 783-794.
11. Cui R. Management strategies for patients with placenta accreta spectrum disorders who underwent pregnancy termination in the second trimester: a retrospective study. *BMC Pregnancy Childbirth.* 2018; 18(1): p. 298.
12. Morgan M and R Atalla, Mifepristone and Misoprostol for the management of placenta accreta - a new alternative approach. *BJOG.* 2009; 116(7): p. 1002-3.
13. Shah D. Mifepristone and Misoprostol vs Misoprostol Alone in Second Trimester Termination of Pregnancy. *JNMA J Nepal Med Assoc.* 2018; 56(213): p. 856-860.
14. Schreiber CA. Mifepristone Pretreatment for the Medical Management of Early Pregnancy Loss. *N Engl J Med.* 2018; 378(23): p. 2161-2170.
15. Xu D. Evaluation of methotrexate-conjugated gadolinium(III) for cancer diagnosis and treatment. *Drug Des Devel Ther.* 2018; 12: p. 3301-3309.
16. Matsubara S. Methotrexate for placenta accreta spectrum disorders: Is it needed? *J Clin Pharm Ther.* 2020; 45(2): p. 399-400.
17. Lin K. Methotrexate management for placenta accreta: a prospective study. *Arch Gynecol Obstet.* 2015; 291(6): p. 1259-64.
18. Kawakatsu S. Population pharmacokinetic analysis of high-dose methotrexate in pediatric and adult oncology patients. *Cancer Chemother Pharmacol.* 2019; 84(6): p. 1339-1348.
19. Zhang C. Retrospective analysis: Conservative treatment of placenta increta with methotrexate. *J Obstet Gynaecol Res.* 2018; 44(5): p. 907-913.
20. Yeou-Lih Wang, Shih-Shien Weng, Wen-Chu Huang. Huang, First-trimester abortion complicated with placenta accreta: A systematic review. *Taiwan J Obstet Gynecol.* 2019; 58(1): p. 10-14.
21. Chen YT. Clinical efficacy and safety of uterine artery chemoembolization in abnormal placental implantation complicated with postpartum hemorrhage]. *Zhonghua Fu Chan Ke Za Zhi.* 2010; 45(4): p. 273-7.
22. Ma YM. Effect of motherwort herb on the myoelectric activity of uterus in rats]. *Zhongguo Zhong Yao Za Zhi.* 2000; 25(6): p. 364-6.
23. Takeda A and W Koike, Conservative endovascular management of retained placenta accreta with marked vascularity after abortion or delivery. *Arch Gynecol Obstet.* 2017; 296(6): p. 1189-1198.