

# Annals of Clinical and Medical Case Reports

Research Article

ISSN 2639-8109 | Volume 9

## Post Angiography Skin Necrosis Treated with Gracilis Muscle Flap- A Case Report

Vijay Bhatia<sup>1,\*</sup>, Kena Patel<sup>2</sup>, Sruja Narola<sup>2</sup>, Ranjit Zapadiya<sup>2</sup>, Rahul Kaushik<sup>2</sup>, Archana Thakur<sup>2</sup>, Manisha Singh<sup>2</sup> and Deepanjali Kalra<sup>2</sup>,

<sup>1</sup>Department of Plastic & Reconstructive Surgery, Vadilal Sarabhai General Hospital & NHL Medical College Ahmedabad, India

<sup>2</sup>Resident doctor, Smt. NHL Municipal Medical College, SVP Hospital, Ahmedabad, India

### \*Corresponding author:

Vijay Bhatia,  
Department of Plastic & Reconstructive Surgery,  
Vadilal Sarabhai General Hospital & NHL  
Medical College Ahmedabad, India,  
E-mail: bhatia101@gmail.com

Received: 04 May 2022

Accepted: 23 May 2022

Published: 27 May 2022

J Short Name: ACMCR

### Copyright:

©2022 Vijay Bhatia,. This is an open access article distributed under the terms of the Creative Commons Attribution License, which permits unrestricted use, distribution, and build upon your work non-commercially.

### Citation:

Vijay Bhatia, Post Angiography Skin Necrosis Treated with Gracilis Muscle Flap- A Case Report. Ann Clin Med Case Rep. 2022; V9(4): 1-5

### Keywords:

Angiography; Hematoma; Necrosis; Gracilis flap

## 1. Abstract

The use of the muscle flaps for the management of complex groin wound with exposed vessels provide effective and safe coverage. The choice of flap is important depending on the size of the wound which gives adequate healthy tissue coverage delivering oxygen and antibiotic to the infected wound bed, which can prevent catastrophic events like vessel blow out. We report here usage of retroflexed gracilis muscle flap for successful covering of the exposed femoral vessels post angiography procedure.

## 2. Introduction

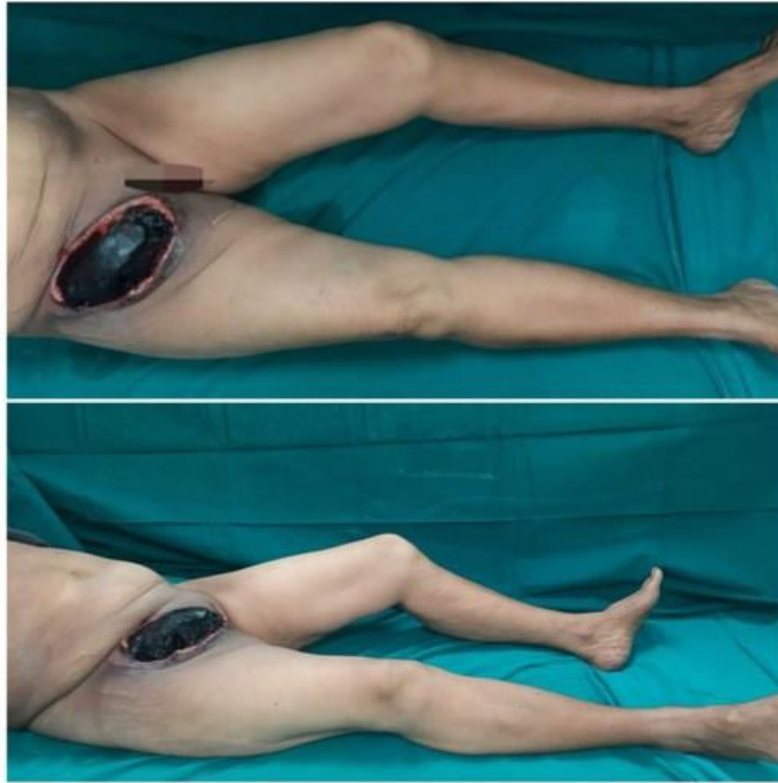
Vascular interventional procedures using transfemoral access site is a common and relatively safe procedure used for treating coronary and limb ischemia for revascularisation. However, complications can arise like bleeding, infection, hematoma, pseudo aneurysm, arterio-venous fistula formation and femoral artery thrombosis, requiring intervention. We report here a similar case where in the patient underwent transfemoral angiography in a private institute and referred to us with a large right groin hematoma with overlying skin necrosis requiring debridement and coverage of groin.

## 3. Case Report

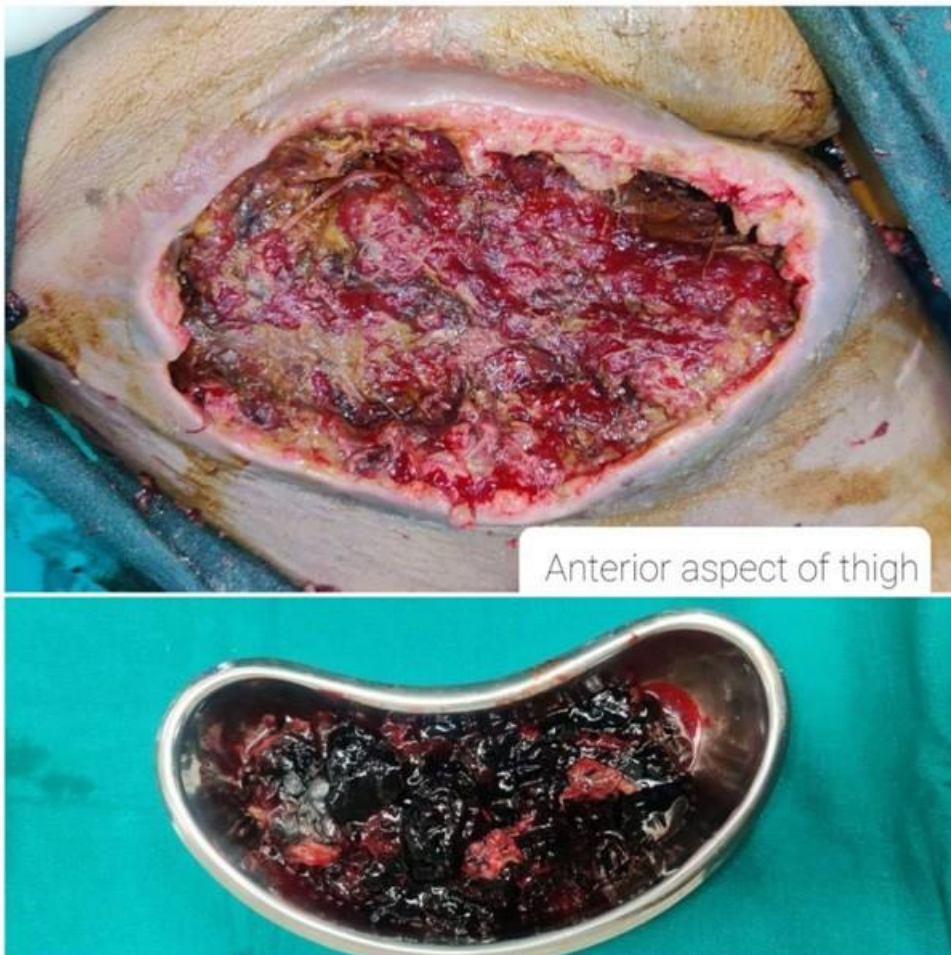A 63 year old female patient presented to us with a hematoma with necrosis of overlying skin in the right groin seen after angiography was done outside for coronary artery disease of single vessel [CAD-SVD], taking access from the right femoral artery. The patient had history of right lower limb pain for which she had sought medical attention in October 2020 from a local hospital and was

managed conservatively without investigating the cause aggressively. The patient later developed severe right lower limb pain on 30 th January 2021, on investigation she was found to have complete occlusion of right distal posterior tibial artery on doppler and CAD-SVD on cardiac angiography. Patient underwent conservative management for posterior tibial artery block and angioplasty for the SVD in at another centre and was discharged the same evening on 30 th January 2021. Post discharge the patient developed pain and swelling in the right inguinal region gradually over a period of 3 days, she visited the out patient department of a near by local hospital where she was transfused 4 units of packed cell for falling haemoglobin and compressive dressings were done for the swelling. The dressings and conservative approach continued for 3 days post which the overlying necrosed skin due to the underlying pressure of the collected hematoma sloughed out [Figure 1].

She was referred to our hospital for further management where she presented on 4<sup>th</sup> February 2021 with Single 15 \* 20 cm hematoma parallel to the inguinal fold 5cm from the anterior superior iliac spine and up to 4 cm inferiorly from pubic tubercle with sloughing of overlying skin cover. Patient underwent relevant blood investigation along with Computed Tomography Angiogram of the lower limb suggestive of patent femoral vessels. After opinion of the cardiovascular department, debridement of the infected hematoma was done and margin of the wound was found to be inflamed and femoral vessels were exposed with resultant defect of 17\* 23 cm. Intraoperative decision was made to cover the vessels with gracilis muscle flap even when primary closure was possible to prevent blow out of the vessels in view of infection of the bed.

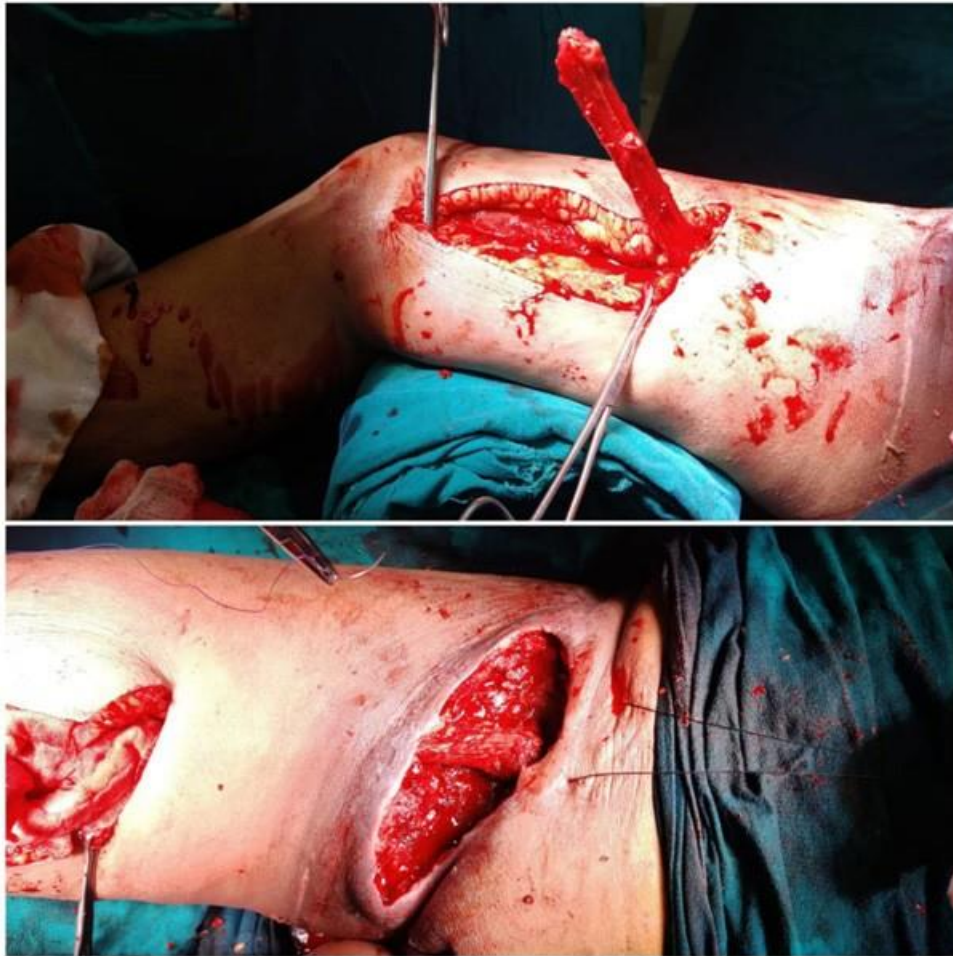

**Figure 1:** Preoperative picture showing hematoma at the right groin post right femoral catheterisation for angiography.

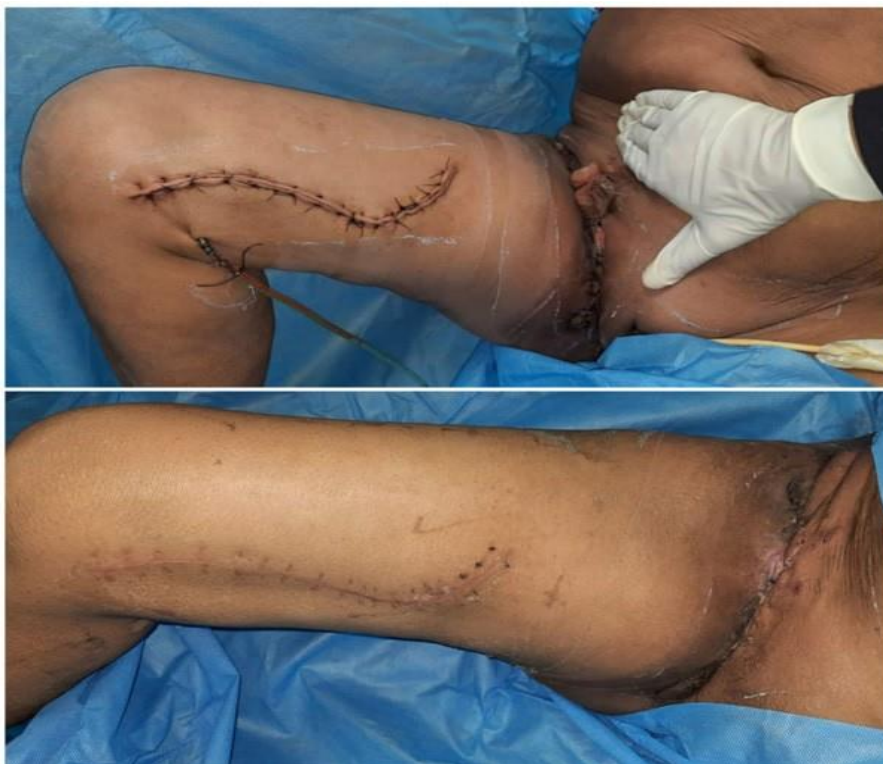

**Figure 2:** Intra operative wound bed after removal of the hematoma.





**Figure 3:** Gracilis flap elevation and using it to give cover to the vessels to prevent further complications; seen here in the second image the healthy wound bed post debridement and gracilis muscle flap in the right groin.



**Figure 4:** Postoperative pictures with healthy suture line.

### 3. Surgical Steps and Ward Follow Up

After surgical prep of the patient the right lower limb is abducted and external rotated, in this position the adductor longus becomes taught which can palpated and its origin traced. Gracilis muscle originates medial to the adductor longus muscle. A line is drawn from the origin of the gracilis to medial femoral condyle. Incision was kept on the distal part of the thigh for a length of 20 cm, the muscle was identified which the most superficial adductor is lying between adductor longus and adductor magnus. The muscle was divided proximal to the musculotendinous junction. Meticulous dissection was done in a distal to proximal manner, stopping short of 10 cm below the pubic tubercle where the vascular pedicle is consistently present. The distal cut end was sutured in a running fashion with absorbable suture to prevent bleeding from the cut end. We mobilised 27 \* 4 cm of the muscle and turned over itself, passing from under the subcutaneous tunnel, in proximal thigh. The retroflexed the distal end of muscle flap and secured in position by suturing to the inguinal ligament and to the overlying skin with a bolster suture, closing the groin defect primarily after flexing the hip to avoid tension on the suture line. Gracilis donor site was closed primarily with negative drain in situ. Patient was advised to keep the right hip flexed to avoid tension on the suture line with plan to gradually straighten the hip starting post operative (post op ) day 15. Suture removal in our department for delayed primary closure is done on post op day 21. Drain from the donor site was removed on day 7 when the drain output reduced to less than 10 cc / day. Patient developed dehiscence of suture line on post-operative day 12 at right groin, and was taken for resuturing maintaining all aseptic precaution. Even with suture dehiscence no blow out occurred as the vessels were covered with muscle flap, and the patient was discharged uneventfully after a total of 25 days. We kept the patient admitted to prevent further complication and discharged the patient after alternate suture removal. On follow up all sutures were removed and patient could mobilize one her own by 40 days post operative day.

### 4. Clinical Anatomy of Gracilis Muscle Flap

The gracilis flap was originally developed as a musculocutaneous coverage option for lower extremity and perineal soft tissue defects, as an alternative to delayed healing of these open wounds [1]. More recently, the retroflexed gracilis muscle flap was reported as a method to provide viable tissue coverage of the femoral vessels after complications of vascular surgery such as groin wound infections and vascular graft infections [2]. The gracilis muscle is the most superficial of the adductor muscles; it originates on the symphysis pubis and pubic arch. It inserts distally onto the medial surface of the tibia. The muscle belly is broad and flat at its origin but tapers to its insertion. It functions to adduct, flex the knee and hip, and medially rotate the hip. As described by Mathes and Nahai, the gracilis has a Type 2 blood supply, one dominant pedicle with several minor pedicles [3]. The dominant pedicle for this flap

is from the descending branch of the medial femoral circumflex artery, although a direct branch from the profunda femoral artery has been described. In most adults, the perforating vessel is found approximately 10 cm inferior to the pubic tubercle. Usually, two vena comitantes accompany the dominant pedicle.

### 5. Discussion

The inguinal area is a crucial intersection of fundamental anatomical structures like femoral artery, vein, nerve, lymph nodes; this makes it a gateway for common vascular intervention for diagnostic and interventional purposes. Any interventional procedure can lead to multiple complications of groin access; vascular complication of the cardiac catheterization and coronary intervention can be divided in to minor and major complications. Minor complications include minor bleeding, ecchymosis, stable hematoma. Major complications include pseudo aneurysm, arterial-venous fistula, Hematoma requiring transfusion, retroperitoneal hematoma, arterial dissection, embolism, thrombosis [4,5].

There are certain patient related risk factors which can lead to complications like female gender, low body weight, obesity, lower body surface area, older age, peripheral vascular disease, renal failure and low platelet count. The patient who presented to us was an old age female with low body weight and low body surface area [4]. Certain procedure related factors which lead to complications like hematoma are longer duration of anti-coagulation, use of thrombolytic agents, larger arterial sheaths, prolonged procedure duration, higher or lower femoral arterial puncture sites, early mobilisation in post catheterisation period and inadequate compression of the access site. Since patient had come with limited documents, we did not have access to the sheath size used and hence can not comment on the same. However it will be better to have arterial access of the common femoral artery, neither too high nor too low, so that post procedure tamponade can be given against the head of femur [6], Avoid multiple puncture and follow a fixed protocol so as to avoid pseudo aneurysms, hematomas and other vascular complications. Adequate explanation and educating the patients for the need of compression dressings and avoiding unnecessary mobilisation for the first three days. A pedicled muscle flap provides satisfactory single stage wound coverage with obliteration of dead space, Gracilis which is used here, is a slender muscle used to cover exposed vessels, and the muscle can be accommodated in the suture line. Following debridement and flap coverage, the wound can be closed primarily to give a satisfactory healing. In order to give adequate cover to the vessels in the groin a muscle flap is a good option for following reasons [7]:

- 1- Muscle forms a well vascularised vehicle to deliver oxygenated blood to the wound bed in the groin.
- 2- Increased blood flow provides a medium for the transport of antibiotic agents to the wound

Advantage of using gracilis flap:

- 1- Supplied by medial circumflex femoral artery which is a branch of profunda femoris artery
- 2- It has pedicled blood supply and not segmental
- 3- Extended flap harvest will reach as high as lower quadrant of the abdomen onto the external iliac artery.
- 4- Widest part of gracilis rests on the femoral triangle in extended harvest technique
- 5- In case of infection and wound dehiscence, it prevents the blow out as vessel is covered with muscle flap.

While a vascularised muscle flap may control the infection and provide durable clinical success to cover the femoral vessel, late infectious complications can still arise requiring antibiotics. Aggressive and wide soft tissue debridement is necessary in grossly infected groin wound to reduce the bacterial burden [8].

## 6. Conclusion

Gracilis muscle flap utilised here gives cover to the femoral vessels and acts a medium to deliver antibiotic via the blood circulation to the infected bed, and prevents direct exposure of the major vessel thus avoiding any major blow out due to sloughing of the vessels. The muscle flap is covered with primary suturing of the skin, thus not requiring any extra cover for the thin muscle; It does not hamper the hip flexion and serves the purpose of a robust shield of protecting the important femoral vessels. Thus gracilis muscle flap can be utilised where groin wound / femoral access site wound complications arise.

## References

1. Orticochea M. The musculo-cutaneous flap method: an immediate and heroic substitute for the method of delay. *Br J Plast Surg.* 1972; 25(2): 106-10.
2. Landry GJ, Carlson JR, Liem TK. The sartorius muscle flap: an important adjunct for complicated femoral wounds involving vascular grafts. *Am J Surg.* 2009; 197: 655-659.
3. Mathes SJ, Nahai F. Classification of the vascular anatomy of muscles: experimental and clinical correlation. *Plast Reconstr Surg.* 1981; 67(2): 177-87.
4. Femoral vascular access-site complications in the cardiac catheterization laboratory: diagnosis and management Shaun Bhatt, Richard Cooke, Ranjith Shetty and Ion S Jovin\* Department of Medicine, Virginia Commonwealth University, McGuire VAMC, 1201 Broad Rock Boulevard 111J, Richmond, VA 23249, USA
5. Hung Fong SS, Jaafar S, Misra S, Narasimha V. Scrotal hematoma with pseudo-aneurysm after transfemoral catheterization. *J Surg Case Rep.* 2019; 2019(2): rjy310.
6. Bangalore S, Bhatt DL. Femoral arterial access and closure. *Circulation.* 2011; 124(5): e147-56.
7. Calderon W, Chang N, Mathes SJ. Comparison of the effect of bacterial inoculation in musculocutaneous and fasciocutaneous flaps. *Plastic and Reconstructive Surgery.* 1986; 77(5): 785-794.

8. Morasch MD, Sam AD 2nd, Kibbe MR, Hijawi J, Dumanian GA. Early results with use of gracilis muscle flap coverage of infected groin wounds after vascular surgery. *J Vasc Surg.* 2004;3 9(6): 1277-83.