

Dislodgement of Left Main Stent Following Intravascular Imaging: How the Technician Disclosed Distracted Stent and Prevented Potential Serious Complications

Al-Nooryani A¹, Khashaba A¹, Ammar A¹, Najib R¹ and Beleslin B^{2*}

¹Al Qassimi Hospital, Sharjah, United Arab Emirates

²Medical Faculty, University of Belgrade, Serbia

*Corresponding author:

Branko Beleslin,
Medical Faculty, University of Belgrade, Belgrade,
Serbia, Tel: +381638328690;
E-mail: branko.beleslin@gmail.com

Received: 26 May 2022

Accepted: 07 Jun 2022

Published: 13 Jun 2022

J Short Name: ACMCR

Copyright:

©2022 Beleslin B. This is an open access article distributed under the terms of the Creative Commons Attribution License, which permits unrestricted use, distribution, and build upon your work non-commercially.

Citation:

Beleslin B, Dislodgement of Left Main Stent Following Intravascular Imaging: How the Technician Disclosed Distracted Stent and Prevented Potential Serious Complications. *Ann Clin Med Case Rep.* 2022; V9(7): 1-5

Keywords:

Complex left main stenting; Intravascular imaging;
Distracted stent

1. Abstract

A 54-years old patient with chronic ischemic heart disease and type 2 diabetes mellitus presented with multivessel coronary artery disease. Complex left main coronary stenosis was treated successfully with 2 stents using Culotte technique followed by stent optimization with intravascular imaging. However, one hour later Cath lab technician during copying images on CD observed that the stent contours from Cx artery were missing. The patient was brought back to Cath lab and distracted stent in the left main was successfully managed.

2. Key Clinical Message

Intravascular imaging may be associated with rare complications, which if unrecognized may have life-threatening consequences. Careful management and manipulation of all devices utilized during PCI procedure with final image and patient evaluation is mandatory to prevent serious adverse events.

3. Introduction

The use of intravascular imaging provides unique opportunity to assess underlying mechanisms of stent implantation including complications such as stent underexpansion, dissections and stent failures. In the current era of interventional cardiology particular attention is paid to the optimization of the final results of stenting which remains crucial in regard to potential complications and re-intervention. So, both IVUS and/or OCT should be used to detect in-stent mechanical problems leading to complications and

restenosis [1]. Both modalities are safe, although rare complications related to intravascular imaging have been reported earlier [2, 3].

We present a rare complication of stent distraction following intravascular imaging after complex Left Main (LM) bifurcation stenting that was detected by Cath Lab technician, emphasizing how important for good patients' care is careful manipulation, but also engagement and responsibility of all Cath Lab staff during and after the procedure.

4. Case Presentation

A 54-years old male patient with chronic ischemic heart disease, stable angina, and type 2 diabetes mellitus, was referred to our Cath Lab for diagnostic angiography. His coronary risk factors included also hypertension, smoking, and dyslipidemia. He was taking aspirin 100mg, ramipril 1.25mg, atorvastatin 20mg and glucophage 2x1000mg. On echocardiography he had impaired left ventricular function with ejection fraction of 35-40% due to severe hypokinesia of the mid and apical septum, apex, and mid and apical anterior wall. Diagnostic angiography revealed multivessel disease with bifurcational left main (LM) lesion (Medina 1, 1, 1) (Figure 1a), mid segment sub-occlusion of the left anterior descending artery (LAD) with TIMi 2 flow (Figure 1b), significant lesion of obtuse marginal branch (OM) of the circumflex artery (Cx), and significant lesions in the Right Coronary Artery (RCA). The patient refused surgical revascularization, and the Heart team of our hospital agreed to perform percutaneous coronary intervention

(PCI) of LM, LAD, and OM, and staged procedure of the RCA. On admission, the patient was asymptomatic, his ECG showed sinus rhythm with biphasic T waves in V2-3, and negative T waves in V4-6. His blood pressure was 130/80mmHg, heart rate 73 beats/min, SpO2 was 98%. His blood count, renal and liver functions were normal. PCI was performed from right radial artery, and after heparin premedication coronary wires were placed in distal LAD and OM. The subocclusion of mid LAD was successfully passed with Gaia Second (Asahi), and after predilation 2 drug-eluting stents (DES) Xience Alpine 3.0x28 mm and Xience Sierra 2.75x15 mm (Abbot Vascular) were placed in proximal-to-mid LAD segment. Following predilation of LM to LAD, and LM to Cx artery, Culotte technique was used to treat bifurcational LM stenosis with first DES Xience Sierra 3.5x18 mm (Abbot Vascular) implanted in LM-Cx artery, and after rewiring and strut opening, second DES Xience Sierra 4.0x33mm (Abbot Vascular) was implanted in LM-LAD (Figure 1c) with kissing and final Proximal Optimization (POT) with NC Trek balloon 5.0x15mm (Abbot) (Figure 1d). The intervention was concluded with Kodama HD intravascular imaging (IVUS) catheter (Acist) showing good apposition of stents, and no dissection, with some difficulties with pulling back of the IVUS catheter from the Cx artery. At the end of procedure, the patient was free of angina and ECG was normal. However, one hour later during copying of the patients' angio images to CD, Cath Lab technician noticed that the contours of stent in Cx artery are missing (Figure 2a), and immediately alarmed the interventional cardiologist performing the procedure. The patient was immediately returned back to the Cath Lab, right femoral artery was punctured and 7F femoral sheath was introduced. Angio images of the left main disclosed preserved appearance and coronary flow (Figure 2b) but distracted stent from Cx into LM (Figure 2c) confirmed by stent boosting (Figure 2d) and Dragonfly Optis optical coherence tomography (OCT) imaging catheter (Abbot) (Figure 3). There was no complication or other distractions regarding stents in LAD and LM-LAD. Coronary wires were placed again into distal LAD and distal Cx-OM, and predilation of ostial Cx was performed with Trek balloon 2.5x15mm (Abbot), followed with balloon kissing with NC Quantum Apex balloons (Boston Scientific) of the distal LM (4.0x15mm). Stent Xience Sierra 4.0x28mm (Abbot Vascular) was positioned and implanted from ostial LM into Cx (Figure 4a and b), with final optimization (NC Trek 5.0x15mm, Abbot) of the proximal LM. After recrossing of the coronary wire into distal LAD, and predilation of stent struts, final balloon kissing of LM, and final POT with NC Trek balloon 5.0x12 mm (Abbot) was performed (Figure 4c). Finally, stenosis in OM branch was treated with DES Xience Alpine 2.75x23 mm (Abbot Vascular), and followed by final optimization with NC Quantum Apex balloon 3.5x6mm (Boston Scientific) (Figure 4c). Final OCT confirmed good result. Three weeks later, the patients presented to Cath Lab for staged PCI of RCA and re-assessment of LM. Distal bifurcation RCA ste-

nosis was treated with Culotte technique with 2 DES Xience Sierra (Abbot Vascular) 2.25x38mm and Xience Sierra (Abbot Vascular) 2.5x28mm in PD and PL branch respectively, whereas proximal RCA stenosis was treated with Xience Alpina (Abbot Vascular) 4.0x28mm (Figure 5a and b). Angio of LM showed no significant lesions of LM and other treated lesions (Figure 5c), but disclosed small area of haziness in the distal part of LM (Figure 5d), that was considered for intensive triple antithrombotic treatment including rivoroxaban, clopidogrel and aspirin and scheduled for OCT imaging after a couple of days. Repeated echocardiography showed improvement in systolic function with ejection fraction of 45%, and mild hypokinesia of septum, mid and apical anterior wall. Control angio and OCT imaging with DragonFly Optis (Abbot) after 7 days, showed a tissue protrusion in the distal LM, with stable organized thrombus, as well as several well opposed layers of stent struts in the LM (Figure 5e). The patient was left on triple antithrombotic therapy with suggestion for staged imaging after 3 months. Angio imaging three months later disclosed minor in-stent restenosis of ostial LAD (Figure 5f), with significant in-stent restenosis of both proximal and distal RCA, that was successfully treated with drug-coated balloons.

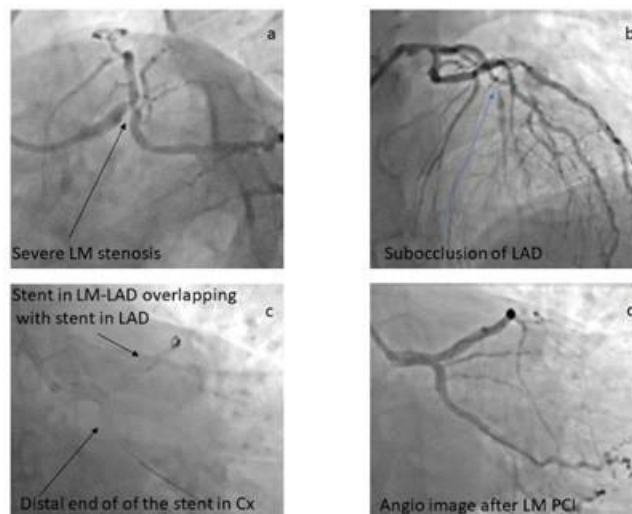


Figure 1:

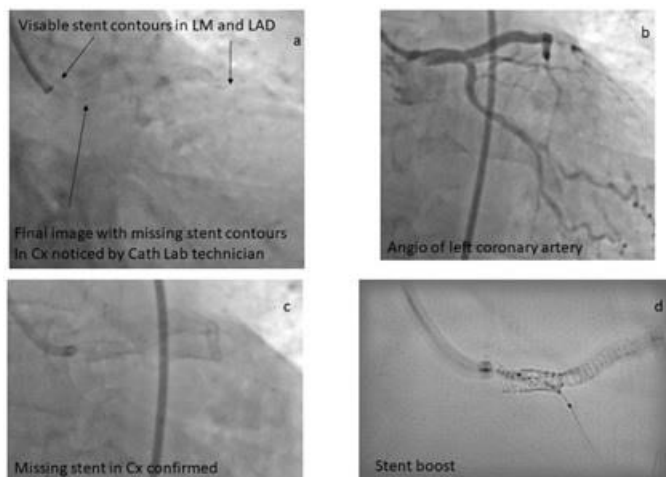


Figure 2:

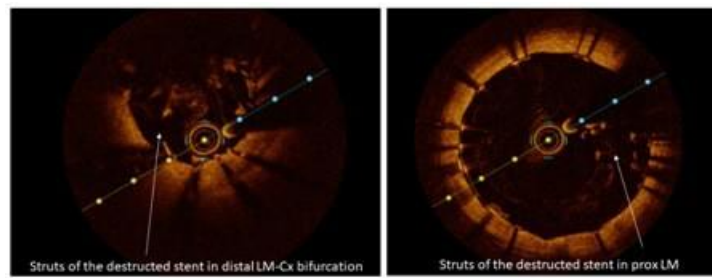


Figure 3:

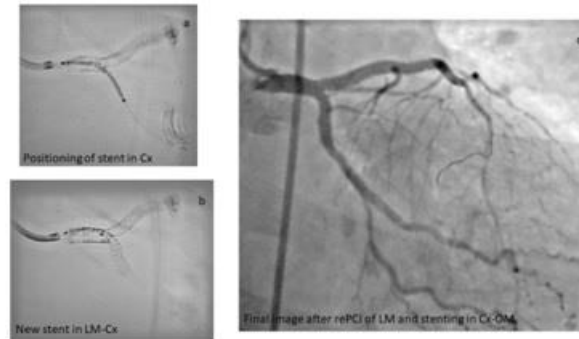


Figure 4:

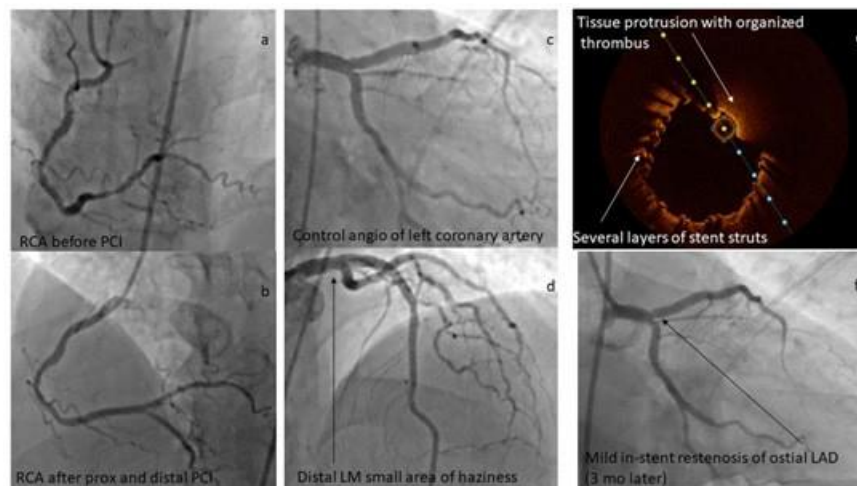


Figure 5:

5. Discussion

We present a rare case of stent distraction during pull-back of intravascular imaging device (IVUS) after LM bifurcation stenting with Culotte technique, which was uneventful during procedure but noticed by the Cath lab technician while copying of the angio images to the CD. Possible mechanism is not easy to appreciate and most probably include distal coronary wire escalation around the struts of the Cx stent behaving like a snare to catch and distract the stent during intravascular device pull-back. We present a video presentation (supplementary material) of probably mechanisms to understand how intravascular device with severely curved coronary wire which looks like a snare can induce stent distraction with stronger and careless pullback following Culotte bifurcation stenting in the LM.

Both IVUS and OCT imaging are indicated for assessment of

LM stenting [1]. IVUS and OCT are based on differing imaging principles, and each carries certain advantages according to the specific clinical situation, but also clinical experience and preference. IVUS may be superior in the diagnosis and management of patients with LM, renal dysfunction, aorto-coronary ostial lesions, and chronic total occlusions [4]. In particular, visualization of the vessel with IVUS enables one to acquire a larger stent area compared with OCT. On the other hand, OCT has higher spatial resolution to IVUS, but lower penetration rate and requires blood clearance from the lumen to allow fine imaging. OCT is superior to IVUS in assessing the etiology of stent failure, and possible causes of ischemia in patients without or milder forms of angiographically non-obstructive coronary artery disease [4]. In fact, OCT has been upgraded in the last European guidelines into Class IIa indication, or should be considered for stent optimization [1]. Because of potential advantages in vessel sizing, IVUS should be consid-

ered for assessment of severity of unprotected LM, but also should be taken into account in case of stent failure in order to correctly understand underlying mechanisms [1]. Therefore, both IVUS and OCT have been recommended to optimize final results of stent implantation, with IVUS having particular role in LM stenting [1]. In addition, a recent meta-analysis of 5,532 patients from 11 clinical trials showed statistically significant reductions in cardiovascular mortality, and stent thrombosis with IVUS-guided PCI compared with conventional angiography [5]. This was confirmed with another meta-analysis, where IVUS was particularly beneficial in complex coronary lesions such as left main disease, bifurcations, acute coronary syndrome and chronic total occlusions (CTO) [6]. Regarding left main procedures, a few randomized trials compared IVUS-guided to conventional angio-guided PCI [7-9], and demonstrated a substantial reduction in cardiac mortality, myocardial infarction, and stent thrombosis with IVUS-guided LM PCI, both in short and long-term follow-up.

Regarding direct comparison between OCT and IVUS guided PCI several studies showed no difference in the outcome and target vessel failure, but attained larger minimal stent area after PCI in IVUS-guided procedures [10, 11]. This was likely driven by sub-optimal visualization of the EEM with OCT in relevant number of patients.

Tissue protrusion, as also demonstrated in our patient, is a common phenomenon following stenting. Tissue protrusion indicates larger stent expansion when seen on IVUS. It is typically not associated with worse outcomes unless there is lumen compromise that could lead to stent thrombosis. Still, asymmetrical tissue protrusion has been linked to target vessel failure [12].

Safety and Complications

The incidence of complications in a large series of intravascular imaging-guided procedures is rare (. Previous registry (2) including 1142 OCT procedures and 2476 IVUS procedures, has demonstrated a similar rate of complications of the two imaging methods (OCT: n=7, 0.6%; IVUS: n=12, 0.5%; p=0.6), and included transient ST-elevation (OCT =0.26% and IVUS =0.08%), bradycardia (OCT =0.18% and IVUS =0.04%), coronary spasm (OCT =0.09% and IVUS =0.04%), thrombus formation (OCT =0.09% and IVUS =0.16%), dissection (OCT =0% and IVUS =0.12%), and stent deformation (OCT =0% and IVUS =0.04%) [2]. Most of these complications were self-limiting following imaging catheter removal. There were no IVUS or OCT-related mortalities, or permanent harm for the patient [2]. The 5-year results of the IVUS-XPL trial [13] further support the health-economic impact of using IVUS.

5. Conclusions

Intravascular imaging plays an important role in contemporary PCI for optimizing stent and patient-oriented outcomes. However, potential serious complication may occur following complex and exhausting procedures with final stent optimization following in-

travascular imaging [2, 3]. Two important messages are pertinent to this case: 1) strong and vigorous pull-back of intravascular imaging catheters after PCI should be avoided, whereas distal coronary wire should be carefully observed and gently removed from the coronary artery at the end of the procedure, and 2) all members of Cath lab team should be engaged in the safety of the procedure regardless of the time spent in Cath Lab and complexity of the procedure. We express our gratefulness to members of our team who mindfully follow the case and observed potentially life-threatening complication of complex LM stenting with intravascular imaging.

References

1. Neumann FJ, Sousa-Uva M, Ahlsson A, et al. ESC Scientific Document Group. 2018 ESC/EACTS Guidelines on myocardial revascularization. *Eur Heart J*. 2019; 40: 87-165.
2. van der Sijde Jn, Karanasos A, van Ditzhuijzen NS, et al. Safety of optical coherence tomography in daily practice: a comparison with intravascular ultrasound. *Eur Heart J – Cardiovasc Imaging*. 2017; 18: 467-74.
3. Batkoff BW, Linker DT. Safety of intracoronary ultrasound: data from a Multicenter European Registry. *Cathet Cardiovasc Diagn*. 1996; 38: 238-41.
4. Ono M, Kawashima M, Hara H, et al. Advances in IVUS/OCT and future clinical perspective of novel hybrid catheter system in coronary imaging. *Front Cardiovasc Med*. 2020; 7: 594899.
5. Kumar A, Shariff M, Adalja D, et al. Intravascular ultrasound versus angiogram guided drug eluting stent implantation. A systematic review and updated meta-analysis with trial sequential analysis. *Int J Cardiol Heart Vasc*. 2019; 25: 100419.
6. la Torre Hernandez JM, Baz Alonso JA, Gómez Hospital JA, et al. Clinical impact of intravascular ultrasound guidance in drug-eluting stent implantation for unprotected left main coronary disease: pooled analysis at the patient-level of 4 registries. *JACC Cardiovasc Interv*. 2014; 7: 244-54.
7. Liu XM, Yang ZM, Liu XK, et al. Intravascular ultrasound-guided drug-eluting stent implantation for patients with unprotected left main coronary artery lesions: A single-center randomized trial. *Anatol J Cardiol*. 2019; 21: 83-90.
8. Wang Y, Mintz GS, Gu Z, et al. Meta-analysis and systematic review of intravascular ultrasound versus angiography-guided drug eluting stent implantation in left main coronary disease in 4592 patients. *BMC Cardiovasc Disord*. 2018; 18: 115.
9. Andell P, Karlsson S, Mohammad MA, et al. Intravascular ultrasound guidance Is associated with better outcome in patients undergoing unprotected left main coronary artery stenting compared with angiography guidance alone. *Circ Cardiovasc Interv*. 2017;10: e004813.
10. Habara M, Nasu K, Terashima M, et al. Impact of frequency-domain optical coherence tomography guidance for optimal coronary stent implantation in comparison with intravascular ultrasound guidance. *Circ Cardiovasc Interv*. 2012; 5: 193-201.
11. Kubo T, Shinke T, Okamura T, et al. Optical frequency domain

- imaging vs. intravascular ultrasound in percutaneous coronary intervention (OPINION trial): one-year angiographic and clinical results. *Eur Heart J.* 2017; 38: 3139-47.
12. Soeda T, Uemura S, Park SJ, et al. Incidence and clinical significance of poststent optical coherence tomography findings: one-year follow-up study from a multicenter registry. *Circulation.* 2015; 132: 1020-9.
 13. Hong SJ, Mintz GS, Ahn CM, et al. Effect of intravascular ultrasound-guided drug-eluting stent implantation: 5-year follow-up of the IVUS-XPL randomized trial. *JACC Cardiovasc Interv.* 2020; 13: 62-71.