

Transcatheter Arterial Embolization of the Common Hepatic Artery for Pseudoaneurysm after a Laparoscopic-Assisted Pancreaticoduodenectomy: A Case Report

Lifeng Xu^{1,3}, Bo Yang¹, Guosheng Gu^{2,3,*} and Yongxiang Li^{1*}

¹Department of General Surgery, The First Affiliated Hospital of Anhui Medical University, Hefei, Anhui, People's Republic of China

²Department of General Surgery, Jinling Hospital, Nanjing University School of Medicine, Nanjing, Jiangsu, People's Republic of China

³Department of General Surgery, Anhui No.2 Provincial People's Hospital, Hefei, Anhui, People's Republic of China

*Corresponding author:

Yongxiang Li,

Department of General Surgery, The First Affiliated Hospital of Anhui Medical University, Hefei, Anhui, People's Republic of China, Tel: +86 1361 5601 088, E-mail: liyongxiang@ahmu.edu.cn and

Guosheng Gu,

Department of General Surgery, Jinling Hospital, Nanjing University School of Medicine, Nanjing, Jiangsu, People's Republic of China, Tel: +86 13856524967, E-mail: guguoshengde@163.com

Received: 15 Sep 2022

Accepted: 10 Oct 2022

Published: 17 Oct 2022

J Short Name: ACMCR

Copyright:

©2022 Yongxiang Li, Yongxiang Li. This is an open access article distributed under the terms of the Creative Commons Attribution License, which permits unrestricted use, distribution, and build upon your work non-commercially

Citation:

Yongxiang Li, Yongxiang Li, Transcatheter Arterial Embolization of the Common Hepatic Artery for Pseudoaneurysm after a Laparoscopic-Assisted Pancreaticoduodenectomy: A Case Report. *Ann Clin Med Case Rep.* 2022; V10(2): 1-6

Keywords:

Laparoscopic pancreaticoduodenectomy; Pseudoaneurysm of common hepatic artery; DSA; Microcoil embolization; Postoperative complications

1. Abstract

Common hepatic artery (CHA) pseudoaneurysm is a rare and potentially life-threatening complication after pancreaticoduodenectomy, and the possible cause is unclear. We report a case of intra-peritoneal hemorrhage after pancreaticoduodenectomy who was discharged after embolization under DSA. We consider that this complication may be related to iatrogenic injury.

2. Key Clinical Message

Intra-peritoneal hemorrhage is one of the serious postoperative complications. We found the pseudoaneurysm of common hepatic artery after laparoscopic pancreaticoduodenectomy by DSA and used microcoil embolization for cure. We reviewed the procedure of laparoscopic surgery and identified several factors that might reduce postoperative bleeding.

3. Introduction

Pancreaticoduodenectomy (PD) is the main procedure for some surgeries related to the pancreas. Due to the advance of the surgical technology in recent two decades, mortality decreased considerably [1]. However, the morbidity rate for the major complication

after PD remains high [2]. In the various complications, postpancreatectomy hemorrhage (PPH) is a fatal complication, which is linked with 11%–38% of the overall mortalities [3-6]. According to the International Study Group of Pancreatic Surgery [7], late PPH is caused by a ruptured pseudoaneurysm. Once the pseudoaneurysm ruptures, laparotomy and endovascular intervention are the main treatment to be done. Here, we report the clinical features, diagnosis, and treatment of a case of pseudoaneurysm formation due to massive hemorrhage in the common hepatic artery (CHA) after PD. Finally, we used the microcoils under DSA to block the common hepatic artery, to prevent further bleeding.

4. Case Report

A 48-year-old male patient underwent a modified Child PD for the malignant tumor of the descending duodenum. He had right upper quadrant pain for 3 months. The pain started 30 minutes after eating and relieved after defecation. There was no chills, fever, and diarrhea. Physical examination revealed a blood pressure = 144/90 mmHg, pulse = 84 beats/min, BMI = 27.40. The whole abdomen was slightly distended, tender to palpation, no tenderness, no rebound tenderness, and no pulsatile abdominal mass. Digital rectal exam-

ination was negative. CA19-9 was 14.15U/ml, CEA was 2.38ng/ml. The gastroscopy and abdominal enhanced computed tomography (CT) in the preoperative examination are displayed in Figure 1. The related index and laboratory values of the patients showed no abnormal outcomes. Standard modified Child PD was performed after excluding the surgical contraindications. No adverse events occurred during the operation. Antibiotic prophylaxis was administered in the postoperative treatment. On postoperative day (POD) 2, the patient suffered from fever and abdominal pain. Persistent peritoneal lavage and drainage were conducted to prevent anastomotic leakage. On POD 8, the continuous drainage stopped because of disappearing abdominal pain. On POD 10, the patient had a sudden abdominal pain and showed 50 mL loss of blood from the drain of cholangiojejunostomy. Hemoglobin concentration decreased to 85 g/L, which had dropped by 45 g/L compared to the last inspection. At the same time, the amylase level measured in the intra-abdominal drainage fluid was 1480u/L. In terms of diagnosis, pancreatic fistula and intra-abdominal bleeding were considered. Conservative treatment, including fluid infusion, use of hemostatic agents, and blood transfusion, was used for this patient. Then, the patient's condition was stabilized gradually. Abdominal CT was performed on the POD 19, which revealed the existence of bloody fluid collection around the perihepatic area (Figure 2). On POD 21, the patient underwent catheter drainage under the guidance of ultrasonic from the perihepatic area. Abdominal dis-

tension of the patient improved. However, on POD 25, the patient abruptly developed melena and hematemesis, and vomited about 300 mL of bloody fluid. A total of 200 mL bright red bloody fluid drained from the abdominal tube. Then, the patient suffered from a shock with hypotension and tachycardia. Hence, Active abdominal bleeding was considered. Urgent Digital Subtraction Angiography (DSA) performed on the basis of a joint decision between the interventional radiologist and a surgeon. DSA revealed a pseudoaneurysm after the rupture of the CHA (Figure 3a, Video 1). Then, embolization of the hepatic artery with microcoil was performed successfully (Figure 3b, Video 2). The patient's blood pressure returned to normal after embolization. And then the patient regained hemodynamic stability and was transferred to the Intensive Care Unit (ICU). The patient was successfully discharged from the hospital on POD 38. Postoperative pathology showed moderately differentiated adenocarcinoma in the duodenal papilla, with a size of 2.5x2.0x1.6cm, invading the whole layer of the duodenal wall and nerves. The pancreatic margin, duodenal margin, gastric margin, and common bile duct margin were negative (cutting edge > 5mm). And no metastasis was found in the four lymph nodes. Postoperative pathological stage was pT3N0M0. The patient refused the genetic testing due to economic problems, so there was no diagnosis of MSI or MMR. Followed up for 3 to 6 months, there were no obvious recurrence or metastasis in abdominal CT.

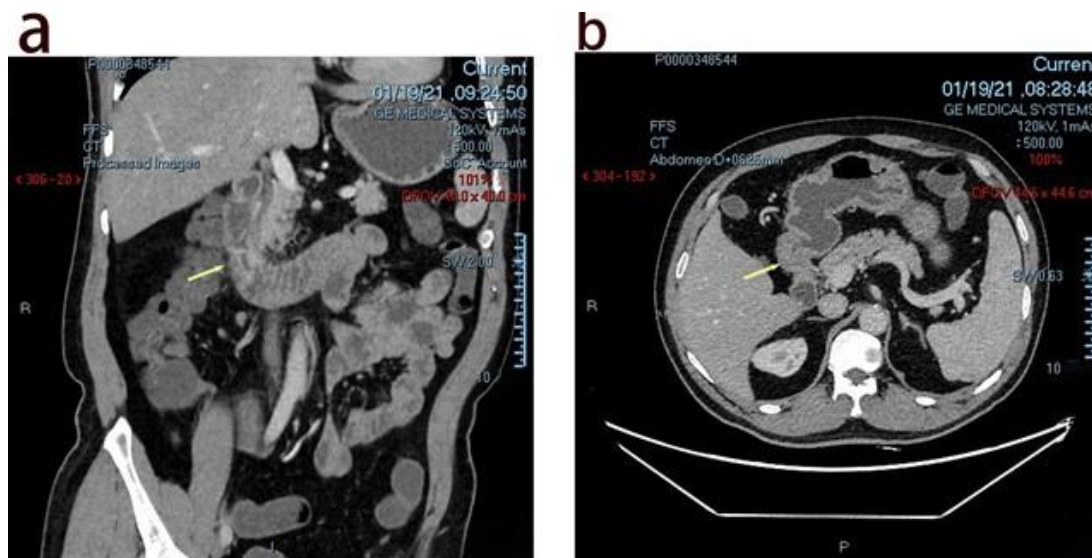


Figure 1: Plain abdominal CT scan revealed lesion of the descending duodenum (yellow arrow). a: Coronal plane view. b: Horizontal plane view.

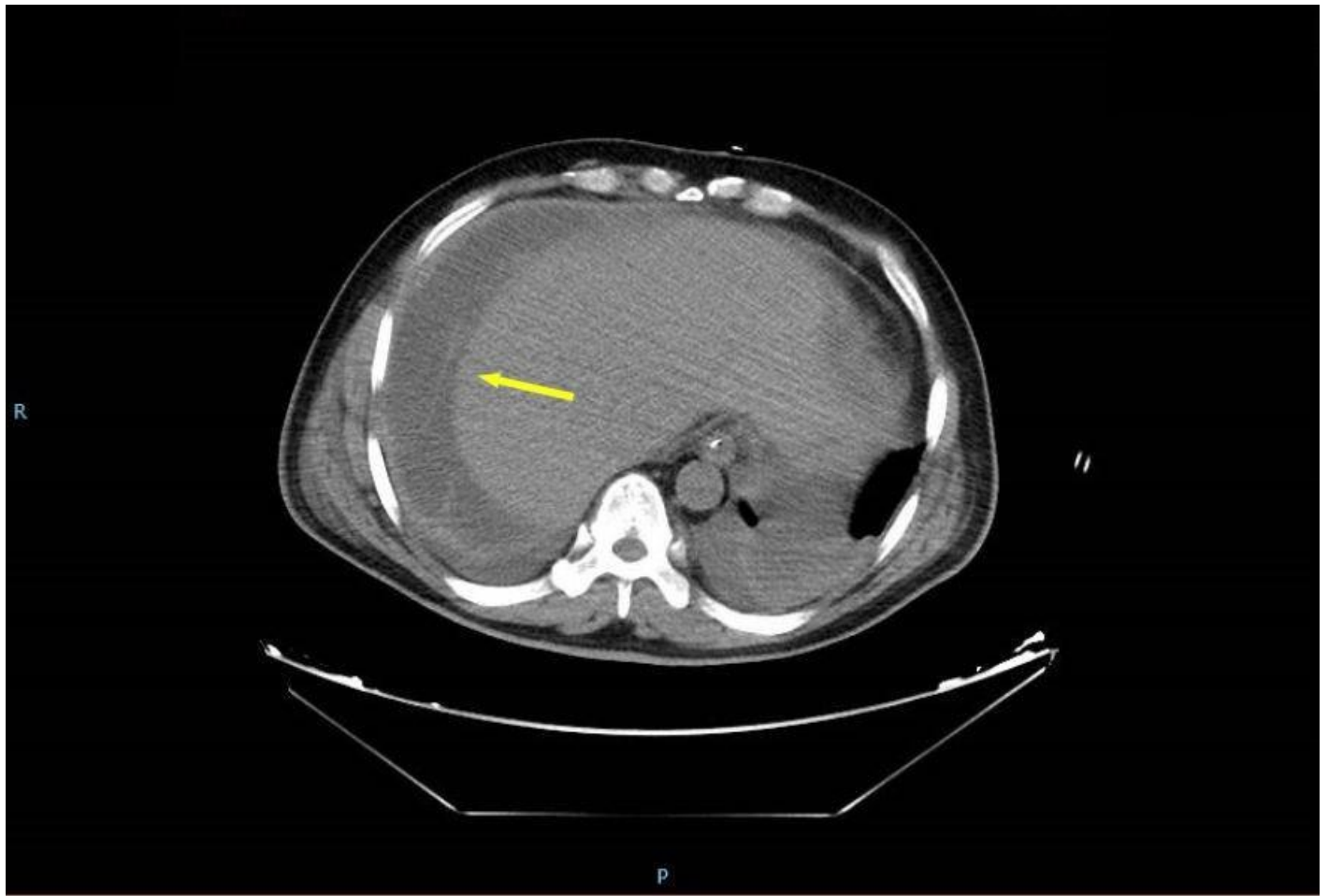


Figure 2:Emergency abdominal CT plain scans showed perihepatic effusion.

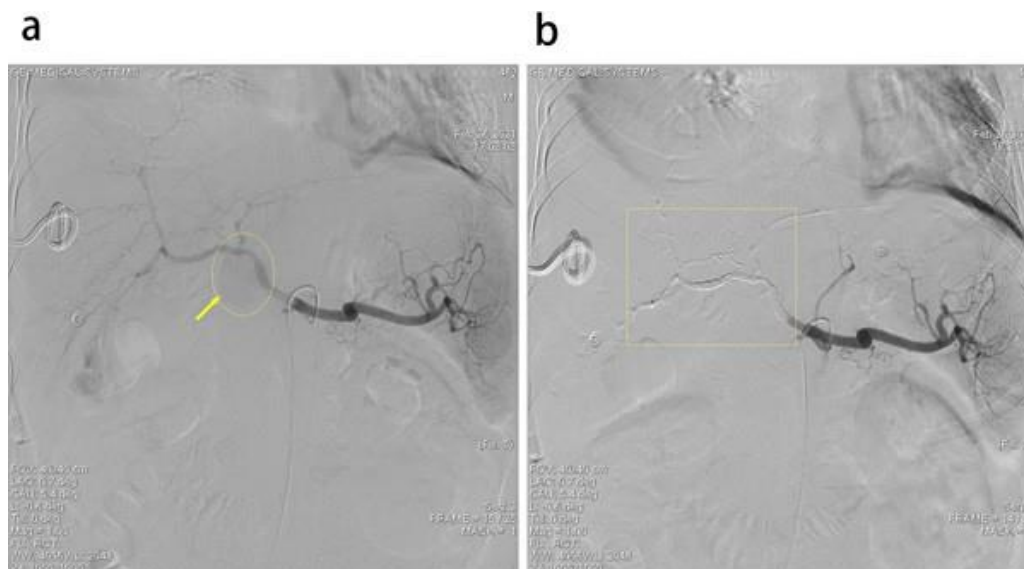


Figure 3: Urgent Digital Subtraction Angiography (DSA). a: pseudoaneurysm of CHA (yellow arrow). b: Successful embolization of hepatic artery with microcoil.

DSAProcedure

The patient lied supine on the DSA table; a puncture in the right femoral artery was performed after local anesthesia. The 5FRH catheter was placed into the right femoral artery, the catheter head was inserted into the celiac trunk artery for DSA, and the super-se-

lected microcatheter (Terumo Progreat microcatheter, Japan) was inserted into the hepatic artery. After the hepatic artery, its branches were identified by contrast; the embolization microcoil was placed, followed by the injection of the histoacryl (B. Braun Closure Specialities, Germany) into the hepatic artery. Ultimately,

the hepatic artery and its branches did not develop again and hence were not visualized under DSA.

5. Discussion

Commonly, complications develop after PD; there is no doubt that PPH is dangerous and fatal. Furthermore, a ruptured pseudoaneurysm is the most severe and fatal cause of PPH [8]. The formation of the pseudoaneurysm is associated with the damage to the vascular wall. Although adequate lymph node dissection and skeletonization of the vessels in surgery may significantly improve the patient's prognosis, the dissection and skeletonization make the arterial wall weak and vulnerable, which is susceptible to erosion by trypsin and elastase from the digestive juice [9]. We made a systematic review of the literature over the 20 years. This descriptive systematic review formulated its research question based on PICO: P – Participants, I – Intervention, C – Comparator, O – Outcomes. The inclusion criteria were P: Patients with pseudoaneurysm after pancreaticoduodenectomy (including laparoscopic assisted), I: Common hepatic artery embolization under DSA, C: Surgery, O: Stop bleeding. Type of article: Multicenter clinical trial, RCT, and Original article. The exclusion criteria were: i, Not all conditions are met (only one or more of the search conditions are met). ii, Full text not retrieved. iii, The type of article is case report or review. The search strategy was “(((embolization)AND (common hepatic artery))AND (pseudoaneurysm))AND (pancreaticoduodenectomy)”. We systematically searched the following databases: PubMed, Cochrane, Elsevier, Science Direct (SDOS), Springer Link, Online library Wiley, EBSCO and Ovid Embase. The initial literature search identified 623 articles and the remaining 25 after reweighting. No relevant text was retrieved from the bibliography. After screening and data extraction, 8 articles were eligible, we added 2 articles by searching citations, and 10 were finally included in this systematic review. Figure 4 is the flowchart of study selection. The information of all articles included is shown in Table 1. Unfortunately, we were unable to retrieve meaningful reports related to laparoscopic pancreatic surgery. From these 10 articles [17-26], a total of 389 postoperative patients has been included. Only 38.5% of patients with pseudoaneurysms occurred in CHA. The average time from postoperative to diagnosis of pseudoaneurysm was 18.05 ± 1.22 days. Coil embolization was used in about 50% of patients. Combining all articles, we found that the use of coil embolization and covered stent are the two most common treatment methods. However, it is still inconclusive which of the two methods is better or worse. Coil embolization is one of the most common treatment methods, which can effectively block the blood supply of pseudoaneurysm, but it is easy to lead to hepatic artery ischemia. However, the covered stent can take good care of the blood supply of the liver, but the cost is high, and it also needs technology and well anesthesia conditions [10]. Then, we analyzed the pathogenesis of this case, which may be related to laparoscopic instrument operation. Especially, the dissociation of vessels

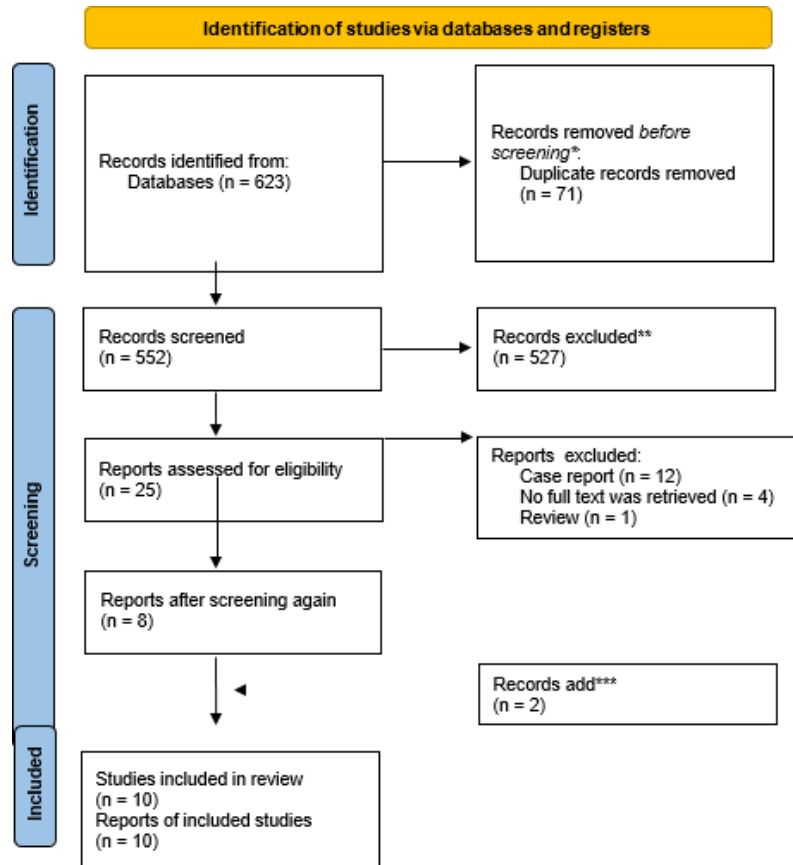
and dissection of the lymph nodes caused excessive skeletonization, and then the Hem-o-lock ligation damaged the arterial wall, which may lead to the formation of the pseudoaneurysm in the stump of the ligated artery. In this case, intraperitoneal hemorrhage occurred after surgery, and the measured drainage liquid amylase was 1480 u/L; thus, it was considered that the digestive fluid leak caused by the pancreatic fistula, corroded the blood vessels, and eventually led to bleeding. After conservative treatment, there is a possibility of hemodynamic instability that would require emergency DSA examination; the formation of a pseudoaneurysm of the CHA and arterial embolism are also considered. Microcoil was chosen given the hemodynamic instability of the patient; while the liver has a double blood supply, a simple embolism is not likely to cause liver ischemia necrosis. Microcoil and histoacryl embolization were chosen given.

A recent meta-analysis revealed that endovascular treatment of a ruptured pseudoaneurysm had low mortality and morbidity and high success rate than surgical intervention [11,12]. Endovascular treatment is considered the first choice in the treatment of pseudoaneurysm recently. Endovascular treatment consists of Transcatheter Arterial Embolization (TAE) and stent-graft placement. Coil embolization as a TAE is an effective approach for the treatment of a pseudoaneurysm [13,14]. In this case, we summarized several experiences for the iatrogenic traumatic pseudoaneurysm. Based on these experiences, we give some possible suggestions on how to avoid and reduce this complication. First, excessive skeletonization of the blood vessels should be avoided, which leads to the injury of the endangium. In addition, when dealing with the stump of the gastroduodenal artery, the lymph nodes should be proper to avert excessive skeletonization. Second, compression, avulsion, clamping, or stretching of the skeletonization vessels in the laparoscopic operation increases the risk of bleeding and may cause injury of the endangium. Therefore, accurate vascular localization is the key to a successful operation, and improper operations should be avoided especially when ligating the arteries. Third, when using the Hem-o-lock to ligate the artery, it should be closed slowly, which avoids the shearing action to vessels in the closure process, and damage to the arterial stump. Finally, the vessels and lymph nodes should be skeletonized with laparoscopic instruments by blunt dissection. According to our experience, the skeletonization of the blood vessel should be covered with a mental flap to prevent hemorrhage after the PD. Several studies [15,16] revealed that the mental flap or falciform ligament placement over a skeletonization of blood vessels could be an effective measure for the prevention of pseudoaneurysm formation after PD. In conclusion, this case demonstrated the successful experience for the treatment of delayed PPH by TAE. Endovascular treatment is the first choice for the diagnosis and treatment of a ruptured pseudoaneurysm after PD. Although a stent-graft placement is considered a first-line treatment in the endovascular treatment, coil emboliza-

tionisreliable,safe,andeffectivemethodparticularlywhenun-stablehemodynamicsofthepatientwasobserved.Inaword,when

making the treatment plan, the patient’s condition, presentation, and clinical history should be taken into consideration.

PRISMA2020flowdiagramformewsystematicreviewswhichincludedsearchesofdatabasesandregistersonly



Use the Find Duplicates function of software (endnote20), except automatically.

**No automation tools used. Contains only 1 or not all search terms.

*** We added 2 articles through Citation retrieval

Figure 4: PRISMA 2020 flow diagram.

Table 1: Basic information for all articles

Author	Year	Patients(n)	CHA ¹ (n)	POD ²	Consequence ³ (n)	Microcoil ⁴ (n)
Yoshitsugu T ⁽¹⁷⁾	2007	4	3 (75.0%)	24.5	0	4(100%)
Lee HG ⁽¹⁸⁾	2010	27	8 (29.6%)	18.3	2	8(29.6%)
Ding X ⁽¹⁹⁾	2011	23	3 (13.0%)	17.7	11	20(87.0%)
Gwon DJ ⁽²⁰⁾	2011	35	7 (0.2%)	15.7	1	3(8.6%)
Lee JH ⁽²¹⁾	2012	27	8 (29.6%)	21	6	21(77.8%)
Cui L ⁽²²⁾	2020	17	16 (94.1%)	15.3	6	0
Hwang K ⁽²³⁾	2020	37	10 (27.0%)	21	0	16(43.2%)
Habib JR ⁽²⁴⁾	2022	130	18 (13.8%)	12	21	59(45.4%)
Tetsuya H ⁽²⁵⁾	2017	27	19(70.4%)	21	8	17(63.0%)
You, Y ⁽²⁶⁾	2019	62	20(32.3%)	14	5	30(48.4%)

1. The bleeding occurred in the common hepatic artery (CHA)
2. Days from postoperative to intervention
3. Number of patients who eventually died
4. Number of patients treated with microcoils

6. Funding Sources

This work was supported by a grant from the National Natural Science Foundation of China (81874063), Natural Science Foundation of Anhui Province (2008085QH408), and Jiangsu Provincial Key Research and Development Program: General social development projects (BE2021727).

References

1. Yoon YS, Kim SW, Her KH. Management of Postoperative Hemorrhage after Pancreatoduodenectomy. *Hepatogastroenterology*. 2003; 50(54):2208-2212.
2. Min W. "Practice Patterns and Perioperative Outcomes of Laparoscopic Pancreatoduodenectomy in China: A Retrospective Multi-center Analysis of 1029 Patients." *Ann Surg*. 2021; 273(1):145-153.
3. Sowmya N, Martin AN, Turrentine F E. Mortality after pancreaticoduodenectomy: assessing early and late causes of patient death. *Journal of Surgical Research*. 2018; 231:304-308.
4. Izumo W, Higuchi R, Yazawa T. Evaluation of preoperative risk factors for postpancreatectomy hemorrhage. *Langenbeck's Archives of Surgery*. 2019; 404(8):967-974.
5. Uggeri F, Nespoli L, Sandini M. Analysis of risk factors for hemorrhage and related outcome after pancreaticoduodenectomy in an intermediate-volume center. *Updates in Surgery*. 2019; 71(4):659-667.
6. Wellner U F, Kulemann B, Lapshyn H. Postpancreatectomy Hemorrhage: Incidence, Treatment, and Risk Factors in Over 1,000 Pancreatic Resections. *Journal of Gastrointestinal Surgery*. 2014; 18(3):464-475.
7. Wente M. Postpancreatectomy hemorrhage (PPH): an International Study Group of Pancreatic Surgery (ISGPS) definition. *Surgery*. 2007; 142.
8. Tessier D J, Fowl R J, Stone W M. Iatrogenic hepatic artery pseudoaneurysms: an uncommon complication after hepatic, biliary, and pancreatic procedures. *Annals of Vascular Surgery*. 2003; 17(6):663-669.
9. Puppala S, Patel J, McPherson S. Hemorrhagic complications after Whipple surgery: imaging and radiologic intervention. *Ajr Am J Roentgenol*. 2011; 196(1):192-197.
10. Massimo Venturini, M, Paolo Marra, Michele Colombo, MD1, et al., Endovascular Treatment of Visceral Artery Aneurysms and Pseudoaneurysms in 100 Patients: Covered Stenting vs Transcatheter Embolization. *J Endovasc Ther*. 2017. 24(5): 709-717.
11. Limongelli, Khorsandi P, Pai SE. Management of delayed postoperative hemorrhage after pancreaticoduodenectomy: a meta-analysis. *Archives of Surgery*. 2008; 143(10):1001-1007.
12. Adam G, Tas S, Cinar C, Bozkaya H, Adam F, Uysal F, et al. Endovascular treatment of delayed hemorrhage developing after the pancreaticoduodenectomy procedure. *Wien Klin Wochenschr*. 2014; 126(13-14):416-21.
13. Reber P U. Superselective microcoil embolization: treatment of choice in high-risk patients with extrahepatic pseudoaneurysms of the hepatic arteries. *J Am Coll Surg*. 1998; 186.
14. Otah, Eseroghene. Visceral Artery Pseudoaneurysms Following Pancreatoduodenectomy. *Archives of Surgery* 2002; 137(1):55.
15. Ray S, Sanyal S, Ghatak S. Falciform ligament flap for the protection of the gastroduodenal artery stump after pancreaticoduodenectomy: A single center experience. *Journal of Visceral Surgery*. 2016; 153(1):9-13.
16. Matsuda H, Sadamori H, Umeda Y. Preventive Effect of Omental Flap in Pancreatoduodenectomy against Postoperative Pseudoaneurysm Formation. *Hepato-gastroenterology*. 2011; 59(114):578-583.
17. L Cui, L Kong, YH Bai, XH Li, XQ Wang, JJ Hao. Covered stent placement for hepatic artery pseudoaneurysm. *Abdom Radiol (NY)*. 2020; 45(10):3337-3341.
18. X Ding, J Zhu, M Zhu, C Li, W Jian, J Jiang, et al. Therapeutic management of hemorrhage from visceral artery pseudoaneurysms after pancreatic surgery. *J Gastrointest Surg*. 2011; 15(8):1417-1425.
19. Di Gwon, GY Ko, KB Sung, JH Shin, JH Kim, HK Yoon. Endovascular management of extrahepatic artery hemorrhage after pancreaticobiliary surgery: clinical features and outcomes of transcatheter arterial embolization and stent-graft placement. *AJR Am J Roentgenol*. 2011; 196(5):W627-634.
20. JR Habib, SGao, AJ Young, EGhabi, AEjaz, WBurns, et al. Incidence and Contemporary Management of Delayed Bleeding Following Pancreatoduodenectomy. *World J Surg*. 2022; 46(5):1161-1171.
21. T Hasegawa, H Ota, T Matsuura, K Seiji, S Mugikura, F Motoi, et al. Endovascular Treatment of Hepatic Artery Pseudoaneurysm after Pancreatoduodenectomy: Risk Factors Associated with Mortality and Complications. *J Vasc Interv Radiol*. 2017; 28(1):50-59 e55.
22. K Hwang, JH Lee, DW Hwang, KB Song. Clinical features and outcomes of endovascular treatment of latent pseudoaneurysmal bleeding after pancreaticoduodenectomy. *ANZ J Surg*. 2020; 90(12):E148-E153.
23. HGLee, JSHeo, SHChoi, DWChoi. Management of bleeding from pseudoaneurysms following pancreaticoduodenectomy. *World J Gastroenterol*. 2010; 16(10):1239-1244.
24. JH Lee, DW Hwang, SY Lee, JW Hwang, DK Song, DI Gwon, et al. Clinical features and management of pseudoaneurysmal bleeding after pancreaticoduodenectomy. *Am Surg*. 2012; 78(3):309-317.
25. TK Yoshitsugu Tajima, Ryuji Tsutsumi, Ichiro Sakamoto, Masataka Uetani, Takashi Kanematsu. Extrahepatic collaterals and liver damage in embolotherapy for ruptured hepatic artery pseudoaneurysm following hepatobiliary pancreatic surgery. *World Journal of Gastroenterology*. 2007; 13(3):408-413.
26. Y You, S H Choi, DW Choi, JS Heo, IW Han. Long-term clinical outcomes after endovascular management of ruptured pseudoaneurysm in patients undergoing pancreaticoduodenectomy. *Ann Surg Treat Res*. 2019; 96(5):237-249.